
Special Topic

Hyperhidrosis: A Review of Current Management

Joanne L. Atkins, M.B.Ch.B., M.Sc., F.R.C.S.(Eng.), and Peter E. M. Butler, F.R.C.S.I., F.R.C.S.(Eng.), F.R.C.S.(Plast.)

London, United Kingdom

Primary hyperhidrosis is a troublesome disorder of excessive perspiration that affects as much as 1 percent of the population. Sufferers are usually young and are often affected by related social, professional, and psychological problems. Many methods for treating hyperhidrosis exist; however, no single treatment is without its weakness or complications. This article aims to clarify the issues related to the use of each treatment modality, including the most recently proposed method using botulinum toxin. (*Plast. Reconstr. Surg.* 110: 222, 2002.)

Hyperhidrosis is a pathologic condition characterized by the secretion of sweat in excess to the normal physiologic needs of the body. Patients seeking medical help often find their work and social lives disrupted by profuse sweating, commonly affecting the axilla, palms of the hand, or soles of the feet. Psychosocial difficulties, physical discomfort, and functional disruption are all problems experienced by this group of patients. Damp hands may be misinterpreted as a sign of anxiety, and damp axillae soaking through clothes are a cause of acute personal embarrassment. Patients may feel physical discomfort related to sodden shoes and clothing, and experience difficulties in performing simple tasks at work, such as handling paper or ink, or gripping work tools.

Hyperhidrosis can be classified as a primary or secondary disease. Primary hyperhidrosis is a disorder of unknown cause and may affect up to 1 percent of the population, although the precise incidence is unknown. The condition commonly manifests in young adults; however, it may present as early as childhood and persist throughout adult life.^{1,2} Secondary hyperhidrosis can arise as a consequence of a number of medical conditions. The long list of possible

causes includes endocrine disease (hypoglycemia, hyperthyroidism), neurologic disorders (syringomyelia, focal lesions of the central nervous system), drug use (antidepressants, antiemetics), the menopause, neoplastic disease (Hodgkin lymphoma, carcinoid tumors, pheochromocytoma), and chronic infection (Table I).^{3,4} Every effort should be made to identify and correct any underlying cause before implementing a treatment plan.

PATHOPHYSIOLOGY OF PERSPIRATION

Human skin contains two functionally distinct types of sweat gland, the eccrine and apocrine glands.

Eccrine Glands

Eccrine glands account for the majority of sweat glands and number approximately 3 million; they produce a thin secretion, hypotonic to plasma, which gives rise to hyperhidrosis if secreted in excess. Eccrine glands are skin appendages that are embryonically derived from the surface epithelium. Each gland consists of a simple coiled secretory portion located deep within the dermis, surrounded by a rich capillary plexus, and supplied by sympathetic postganglionic cholinergic fibers. A long straight duct leads upward from the body of the gland, through the epidermis, eventually opening onto the skin surface.

Eccrine glands are distributed throughout the skin in a common anatomic pattern. Density of distribution varies, depending on the anatomic area, with the greatest density of glands found in the axilla, palm, and sole of the foot.

TABLE I
Causes of Hyperhidrosis

| |
|--|
| Primary |
| Idiopathic |
| Secondary |
| Physiological |
| (i.e., emotion, menopause, hot environment, exercise) |
| Endocrine and metabolic |
| (i.e., thyrotoxicosis, diabetes mellitus) |
| Drugs and substance abuse |
| (i.e., antiemetics, fluoxetine, narcotic withdrawal) |
| Neoplasia |
| (i.e., Hodgkin disease, intrathoracic neoplasms, pheochromocytoma, central nervous system lesions) |
| Cardiovascular and respiratory disorders |
| Febrile illness |

The primary function of sweat secretion is concerned with thermoregulation; however, other accessory functions include maintenance of the health and texture of the skin, with moisture lending traction to the skin surface, a useful function when turning paper or gripping smooth objects. The regulation of the rate and volume of sweat production is normally controlled by the hypothalamus; sensory information related to the core body temperature is integrated and assessed, and measures to increase or decrease the body temperature are initiated. An increase in body temperature leads to changes in both behavior and physiology aimed at temperature reduction. Heat loss through conduction is achieved by the diversion of blood flow to superficial vessels, whereas an increased rate of eccrine sweat secretion leads to heat loss from the skin surface by evaporation. The sympathetic signal leading to this increase in sweat secretion is carried to the eccrine glands through postganglionic cholinergic fibers. The rate of secretion is also increased at times of emotional or physical stress. In primary hyperhidrosis, affected individuals appear to have a raised basal level of sweat secretion and an exaggerated response to the other normal stimuli mentioned.

Apocrine Glands

Apocrine sweat glands are less numerous than eccrine glands and are localized to the axillae and urogenital regions. They become active at puberty and produce a viscid secretion under the control of adrenergic nerve fibers; bacterial breakdown of these secretions by skin commensals produces an unpleasant odor. These secretions do not contribute to hyperhidrosis.

MANAGEMENT OPTIONS

The treatment of patients with primary hyperhidrosis is not straightforward. Conservative therapy with the use of topical agents may be unsuccessful and may lead to surgical referral. Surgical interventions using gland excision, liposuction, or sympathectomy have associated complications that may be unacceptable for the treatment of a benign condition. Botulinum toxin has recently been introduced into the repertoire of existing treatments and can provide a suitable alternative to existing therapies in some circumstances.

The aim of treatment of primary hyperhidrosis is to reduce the volume of sweat secreted to a level that is acceptable to the patient. It is important to understand the motivation and expectations of the patient before embarking on a treatment plan, with appropriate patient counseling for the potential complications and limitations of any treatment. The treatment options available can be considered as conservative or surgical (Fig. 1).

Conservative Treatment

There is a definite role for conservative therapy in the treatment of hyperhidrosis, with a good proportion of patients responding adequately to the current treatments available without recourse to surgery. Although these treatments do not offer a permanent solution to excessive sweating, they often produce acceptable results with minimal morbidity.

Topical agents. Several topical agents have been used as treatment options for hyperhidrosis. Agents applied to the skin achieve their effect either by blocking the excretory ducts of the eccrine glands or are astringent, acting on the sweat glands and the epithelium. A commonly used effective antiperspirant is a saturated solution of aluminum chloride hexahydrate in absolute alcohol. It can be a useful agent in the control of local hyperhidrosis affecting the palms, soles, and axillae, and excellent results have been reported.^{5,6} Drawbacks to this treatment include its short-lived effect, with continued success depending on daily application. Skin irritation is a potential complication of treatment, occurring most frequently in the axillary area, and may be intolerable to some patients. In addition, application of topical solutions can be messy and time consuming, and over prolonged periods of use these difficulties may lead to reduced patient compliance. More-

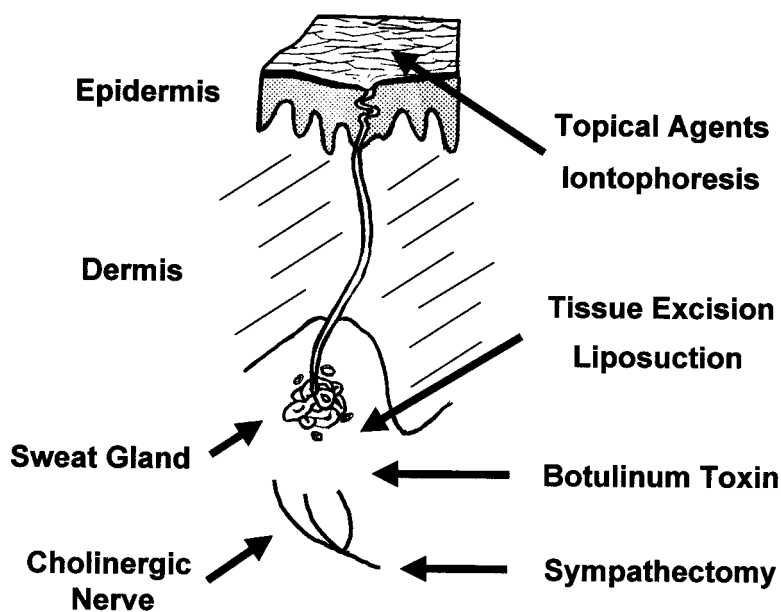


FIG. 1. Summary of conservative and surgical treatment options for hyperhidrosis.

over, a small but significant group of hyperhidrotic patients remain unresponsive to this therapy.⁷

Astringent topical agents that are less commonly used to treat hyperhidrosis include tannic acid and glutaraldehyde. Although they may successfully control sweating, their tendency to stain the skin renders them generally unacceptable to the patient.⁸

Systemic agents. Anticholinergic agents, such as glycopyrronium bromide and propantheline bromide, appear to be a logical choice to systemically decrease the secretion of sweat; however, a number of unpleasant systemic side effects limit their usefulness in clinical practice. Common side effects of these drugs include a dry mouth, blurred vision, urinary retention, and constipation, and generally exclude long-term use.⁹

Benzodiazepines may be useful in decreasing anxiety and reducing the emotional stimulus to excessive perspiration in some patients. These agents may be useful only if taken for brief periods, for example, before an anticipated stressful situation, as long-term use can lead to dependency. Many patients find the effects of lethargy and drowsiness associated with this group of drugs unacceptable.⁷

Iontophoresis. Iontophoresis has been defined as the introduction of an ionized substance through intact skin by the application of direct current. It is a process that can be used with considerable success to treat localized ar-

eas of hyperhidrosis.² The precise mechanism of action is not fully understood; however, it has been suggested it may cause a temporary blockage of the sweat duct at the level of the stratum corneum. A current of 15 to 30 mA can be supplied by a galvanic generator and delivered to the affected area of the body by electrode.⁸ The affected limb, with electrode attached, is either placed in a shallow water bath (using simple tap water), or for other areas such as the axilla, with a moistened cotton wool pad over the electrode.⁵

Good results are achievable, especially for the treatment of the palm and plantar areas, but the treatment is less successful for the axilla. The process needs to be repeated a variable number of times to obtain the desired effect, and maintenance therapy is required. A study of 30 patients required a mean average of 15 treatments to achieve euhidrosis.¹⁰ Duration of euhidrosis can vary from 2 to 14 months after cessation of treatment.

Complications of treatment are generally mild and may include erythema of the treated skin, transient vesicular rash, and transient paresthesia.² Contraindications to treatment include the presence of cardiac pacemakers, pregnancy, or metal orthopedic implants. Conveniently, the treatment is easy to perform, is generally well tolerated, and the patient can be trained to carry it out at home using their own equipment.

Botulinum toxin. Botulinum toxin is a powerful neurotoxin produced by *Clostridium botulinum*. It is currently used to treat a variety of conditions including focal dystonias such as blepharospasm and spasmodic torticollis, and for aesthetic improvement, in particular for the correction of brow-frown lines and periorbital wrinkling.¹¹ Its use as a successful treatment for localized gustatory sweating in Frey syndrome has also been reported.¹²

Botulinum toxin is a zinc-dependent endoprotease that is able to block neurotransmission. It produces this effect through cleavage of the components of the cellular apparatus responsible for the exocytosis of neurotransmitters. In the treatment of hyperhidrosis, botulinum toxin blocks the release of the neurotransmitter acetylcholine, therefore preventing synaptic transmission and producing an effective chemodenervation of the gland and a temporary cessation of sweating.¹³ It is particularly useful in the treatment of focal areas of hyperhidrosis.

Application of the toxin involves multiple injections to the affected hyperhidrotic area. The area can be identified with greater precision by use of the iodine-starch test. Injections are spaced 1 to 2.5 cm apart, with injection dose varying between botulinum toxin products. Currently, botulinum toxin serotype A is the most commonly used. For an axilla or palm, approximately 50 units of toxin are required to achieve an adequate effect.^{4,14} Follow-up suggests a quantitative reduction of sweating of between 70 and 80 percent for the axilla and a 26 to 31 percent reduction after treatment of the palms.^{4,15}

The duration of the therapeutic effect of botulinum toxin varies depending on each individual and the dose given, with a return of sweating reported after a gap of between 3 and 8 months.¹⁴ Reports of continued adequate control of sweating at 1-year follow-up have been reported using a higher dose, with 500 units of botulinum toxin being injected into each axilla.¹⁶

Complications of treatment are generally minor and transient. These include hematoma at the site of injection and paresthesia; however, weakness of the small muscles of the hand can be a problem in the treatment of palmar hyperhidrosis, leading to a reduced force of grip. This may be a more important issue in some patients more than others and should be emphasized during consent for treatment. Anti-

body formation against the toxin remains a possibility and may lead to reduced therapeutic effectiveness.

The major drawback to this treatment is the discomfort associated with the mode of application in the form of multiple injections. This is particularly problematic in the treatment of the palms of the hand and soles of the feet; pain from injection to these sensitive areas may prove to be intolerable to the patient and unacceptable to the surgeon. Application of a topical local anesthetic cream to the injection site before treatment may help in some cases, as may regional nerve block. Unlike the palm and sole, injections to the axilla appear to be very well tolerated, and hyperhidrosis of this area may be a primary indication for the use of botulinum toxin.

Surgical Treatment

Surgery remains a valuable option for the treatment of some cases of hyperhidrosis. Because of a number of potential complications, its use should be reserved for only the more aggressive forms of the disease that remain unresponsive to conservative therapy.

Excision of axillary tissue. Several surgical methods involving excision of axillary tissue can be used to manage hyperhidrosis of the axilla. Three basic types of procedures are described. These include the excision of subcutaneous tissue alone, removal of skin and underlying subcutaneous tissue en bloc, or skin excision with excision of underlying subcutaneous tissue and excision of adjacent subcutaneous tissue.

Breach advocated the first category of procedures that involves the placement of three parallel transverse incisions 1.5 cm in length across the axilla. Through these incisions, the underlying skin of the hyperhidrotic area is undermined and subcutaneous fat is removed in the same fashion as for a full-thickness graft. Of 25 patients (50 axillae) treated with this approach, 23 reported minimal or no sweating at 1 year and were subjectively pleased with the result. The remaining two patients were satisfied with the reduction in sweating and did not require a further procedure.¹⁷ Other surgeons using similar techniques for axillary osmidrosis have found that 79 to 92 percent of patients noted a marked decrease in the volume of sweat produced at long-term follow-up. The reported complication rate appears to be low (4 to 6 percent).^{18,19}

In 1963, Hurley and Shelley described a sim-

ple technique whereby an ellipse of skin was excised from the dome of the axilla and subcutaneous tissue approximately 0.5 cm deep is removed en bloc. The resulting defect is closed directly. Although this simple technique produced favorable results in reducing perspiration, subsequent problems associated with tightness of the axillary fossa from scarring and reduced volume of skin detract from this technique. Modifications of the technique using Z-plasty or a "lazy-S" incision may alleviate these problems.

An alternative technique involves removing a small area of affected skin and subcutaneous tissue en bloc, as well as the removal of subcutaneous tissue alone in the adjacent area.²⁰ The area affected by sweating is marked out using the iodine starch test. A central S shape of skin and underlying tissue is excised as well as the subcutaneous tissue underlying the entirety of the marked area. Design and closure of the flaps as an S avoids the tension of a straight line that is produced using an elliptical excision; excision of the surrounding subcutaneous tissue allows for a more extensive procedure.

Use of the iodine-starch test as originally described by Weaver allows accurate placing of skin incisions over the affected area, thereby including the majority of eccrine glands and improving the likelihood of a satisfactory outcome.^{21,22} Complications associated with surgical removal of skin or subcutaneous tissue from the axilla include wound infection, slow healing, skin edge necrosis, wound hematoma, wound dehiscence, hidradenitis, and axillary hair loss. Scarring can lead to reduced mobility of the shoulder, and incisions and skin closure should be carefully planned.

Axillary liposuction. A technique for subdermal axillary liposuction has been described, carrying out suction via an incision in the anterior axillary fold. The entire subdermal surface can be treated with the cannula holes directed toward the dermis.²³ A similar technique has been used for the treatment of axillary osmidrosis, with reports of a reduction in sweat volume as well as odor.²⁴ The success of the technique may partly be because of disruption of the nerve supply to the sweat glands and removal or destruction of the apocrine glands that are present in the axilla in high density. Liposuction techniques are not yet widely used to treat hyperhidrosis; therefore, the true efficacy of this treatment is unknown.

Thoracoscopic sympathectomy. Sympathetic fibers supplying the eccrine glands of the palm and axilla arise from the T2 to T4 ganglions of the upper dorsal sympathetic chain, respectively. Interruption of the thoracic sympathetic chain is a well-documented method of treating palmar hyperhidrosis, and to a lesser extent axillary hyperhidrosis.²⁵ Interruption of the sympathetic chain leads to permanent cessation of sweating within the nerve distribution. Historically, open procedures were performed to gain access to the thoracic sympathetic chains. These procedures carried a high rate of morbidity, and in recent years have been replaced by minimal-access techniques.

Thoracoscopic interruption of the sympathetic chain requires general anesthesia but can be performed as a short-stay procedure in suitably healthy patients. Patients can usually return to normal activity within a few days after the operation. Contraindications to treatment include respiratory impairment and pleural adhesions. Access to the thoracic cavity is usually gained through the third intercostal space in the anterior axillary line after the collapse of the ipsilateral lung.²⁶ The second, third, and fourth thoracic ganglia are identified and may be ligated with clips before division, although electrocautery may be used as an alternative.¹

In experienced hands, success rates of 87 to 98 percent have been reported for palmar-axillary hyperhidrosis, although treatment for axillary hyperhidrosis alone has been less successful.²⁵ The condition may recur if the chain is incompletely divided, anatomic landmarks are incorrectly identified, or nerve regeneration occurs.

Iatrogenic complications that may arise from the procedure can be serious and include Horner syndrome (transient or permanent), pneumothorax, thoracic duct injury, hemothorax, phrenic nerve damage, and death.²⁷ Side effects of the sympathectomy itself include compensatory sweating, which the patient may find distressing. This can affect as many as 50 percent of patients, being more common in patients with bilateral procedures, and often involves excessive sweating on the trunk, limbs, or face. Gustatory sweating has also been reported following sympathectomy, affecting as many as one-third of patients.²⁸ In patients receiving treatment for palmar hyperhidrosis, it may be wise to treat only the dominant hand involved to reduce the risk of developing compensatory sweating. Permanent nonfunction of

TABLE II
Primary Hyperhidrosis: Treatment Options and
Anatomic Areas

| Method | Area |
|------------------------|---------------------------------|
| Conservative treatment | |
| Topical agents | Palmar, pedal, axilla |
| Iontophoresis | Palmar, pedal, axilla |
| Botulinum toxin | Axilla, focal disease |
| Surgical treatment | |
| Thoracic sympathectomy | Palmar, palmar-axillary disease |
| Tissue excision | Axilla |
| Liposuction | Axilla |

the eccrine glands following sympathectomy may lead to hyperkeratosis, scaling, and fissuring of the skin; this may be distressing for the patient and difficult to treat.⁷

Lumbar sympathectomy for the treatment of pedal hyperhidrosis has been described but is not generally used. In men and women, a complication of the technique may cause sexual dysfunction because of ensuing impotence and anorgasmia.

CONCLUSIONS

Individuals affected by hyperhidrosis incur unpleasant physical and psychological effects stemming from the volume of sweat produced. The majority of patients presenting for treatment of this condition complain of symptoms related mainly to the upper limb, and many have suffered for several years before seeking help. Although many treatment modalities exist, the success of the treatment used varies, depending in part on the area of the body affected and the severity of the problem.

The ideal treatment of choice should be successful, safe, and inexpensive. Conservative treatment should be tried before progressing to the more permanent and usually irreversible effects of surgery. Botulinum toxin is a relatively new treatment and provides good results in achieving euhidrosis over a prolonged period of time. It is particularly useful in the treatment of axillary hyperhidrosis and will probably replace tissue excision or sympathectomy as a treatment for aggressive axillary hyperhidrosis. Focal areas of hyperhidrosis, such as that seen in Frey syndrome, are also easily and adequately treated by botulinum toxin.

Thoracic sympathectomy has a high success rate in achieving relief from hyperhidrosis of the palm alone or in combined disease with the axilla; results are not as satisfactory for treatment of the axilla alone. The serious potential

complications associated with the procedure must be taken into account; however, for patients with disease affecting the axilla and palm, or palm alone, thoracic sympathectomy remains the surgical treatment of choice (Table II).

*Peter E. M. Butler, F.R.C.S.I., F.R.C.S.(Eng.),
F.R.C.S.(Plast.)
Department of Plastic Surgery
Royal Free Hospital
Pond Street
Hampstead
London NW3 2QG
United Kingdom
pembutler@hotmail.com*

REFERENCES

- Byrne, J., Walsh, T. N., and Hederman, W. P. Endoscopic transthoracic electrocautery of the sympathetic chain for palmar and axillary hyperhidrosis. *Br. J. Surg.* 77: 1046, 1990.
- Stolman, L. P. Treatment of excess sweating of the palms by iontophoresis. *Arch. Dermatol.* 123: 893, 1987.
- Leung, A. K., Chan, P. Y., and Choi, M. C. Hyperhidrosis. *Int. J. Dermatol.* 38: 561, 1999.
- Odderson, I. R. Hyperhidrosis treated by botulinum A exotoxin. *Dermatol. Surg.* 24: 1237, 1998.
- Simpson, N. Treating hyperhidrosis. *Br. Med. J.* 296: 1345, 1988.
- Scholes, K. T., Crow, K. D., Ellis, J. P., et al. Axillary hyperhidrosis treated with alcoholic solution of aluminium chloride hexahydrate. *Br. Med. J.* 2: 84, 1978.
- Dobson, R. L. Treatment of hyperhidrosis. *Arch. Dermatol.* 123: 883, 1987.
- Moran, K. T., and Brady, M. P. Surgical management of primary hyperhidrosis. *Br. J. Surg.* 78: 279, 1991.
- Hashmonai, M., Kopelman, D., and Assalia, A. The treatment of primary palmar hyperhidrosis. *Surg. Today* 30: 211, 2000.
- Shrivastava, S. N., and Singh, G. Tap water iontophoresis in palmo-plantar hyperhidrosis. *Br. J. Dermatol.* 96: 189, 1977.
- Garner, W. Review of the use of botulinum toxin for aesthetic improvement. *Ann. Plast. Surg.* 36: 192, 1996.
- Birch, J. F., Varma, S. K., and Narula, A. A. Botulinum toxoid in the management of gustatory sweating (Frey's syndrome) after superficial parotidectomy. *Br. J. Plast. Surg.* 52: 230, 1999.
- Glogau, R. G. Botulinum A neurotoxin for axillary hyperhidrosis: No sweat Botox. *Dermatol. Surg.* 24: 817, 1998.
- Naumann, M., Flachenecker, P., Bocker, E. B., et al. Botulinum toxin for palmar hyperhidrosis. *Lancet* 349: 252, 1997.
- Schnider, P., Binder, M., Auff, E., Kittler, H., Berger, T., and Walsh, T. N. Double-blind trial of botulinum A toxin for the treatment of focal hyperhidrosis of the palms. *Br. J. Dermatol.* 136: 548, 1997.
- Heckmann, M., Schller, M., Ceballos-Baumann, A., and Plewig, G. Follow up of patients with axillary hyperhidrosis after botulinum toxin injection. *Arch. Dermatol.* 134: 1298, 1998.

17. Breach, N. M. Axillary hyperhidrosis: Surgical cure with aesthetic scars. *Ann. R. Coll. Surg. Engl.* 61: 295, 1979.
18. Tung, T. C., and Wei, F. C. Excision of subcutaneous tissue for the treatment of axillary osmidrosis. *Br. J. Plast. Surg.* 50: 61, 1997.
19. Wang, H. J., Cheng, T. Y., and Chen, T. M. Surgical management of axillary bromhidrosis: A modified sk-oog procedure by an axillary bipedicle flap approach. *Plast. Reconstr. Surg.* 98: 524, 1996.
20. Bisbal, J., del Cacho, C., and Casalots, J. Surgical treatment of axillary hyperhidrosis. *Ann. Plast. Surg.* 18: 429, 1987.
21. Weaver, P. C. Axillary hyperhidrosis. *Br. Med. J.* 1: 48, 1970.
22. Davis, P. K. B. Surgical treatment of axillary hyperhidrosis. *Br. J. Plast. Surg.* 24: 99, 1971.
23. Shenaq, S. M., and Spira, M. Treatment of bilateral axillary hyperhidrosis by suction assisted lipolysis technique. *Ann. Plast. Surg.* 19: 548, 1987.
24. Ou, L. F., Yan, R. S., Chen, I. C., and Tang, Y. W. Treatment of axillary bromhidrosis with superficial liposuction. *Plast. Reconstr. Surg.* 102: 1469, 1998.
25. Chaudhuri, N., Birdi, I., and Ritchie, A. J. Current practice in thoracic sympathectomy. *Hosp. Med.* 60: 807, 1999.
26. Malone, P. S., Cameron, A. E. P., and Rennie, J. A. The surgical treatment of upper limb hyperhidrosis. *Br. J. Dermatol.* 115: 81, 1986.
27. Greenhalgh, R. M., Rosengarten, D. S., and Martin, P. Role of sympathectomy for hyperhidrosis. *Br. Med. J.* 1: 332, 1971.
28. Andrews, B. T., and Rennie, J. A. Predicting changes in the distribution of sweating following thoracoscopic sympathectomy. *Br. J. Surg.* 84: 1702, 1997.