

# Cadaveric Study of the Articular Branches of the Shoulder Joint

Maxim S. Eckmann, MD,\* Brittany Bickelhaupt, MD,† Jacob Fehl, MD,† Jonathan A. Benfield, DO,\*  
Jonathan Curley, MD,‡ Ohmid Rahimi, PhD,§ and Ameet S. Nagpal, MD, MS, Med\*

**Background and Objectives:** This cadaveric study investigated the anatomic relationships of the articular branches of the suprascapular (SN), axillary (AN), and lateral pectoral nerves (LPN), which are potential targets for shoulder analgesia.

**Methods:** Sixteen embalmed cadavers and 1 unembalmed cadaver, including 33 shoulders total, were dissected. Following dissections, fluoroscopic images were taken to propose an anatomical landmark to be used in shoulder articular branch blockade.

**Results:** Thirty-three shoulders from 17 total cadavers were studied. In a series of 16 shoulders, 16 (100%) of 16 had an intact SN branch innervating the posterior head of the humerus and shoulder capsule. Suprascapular sensory branches coursed laterally from the spinoglenoid notch then toward the glenohumeral joint capsule posteriorly. Axillary nerve articular branches innervated the posterolateral head of the humerus and shoulder capsule in the same 16 (100%) of 16 shoulders. The AN gave branches ascending circumferentially from the quadrangular space to the posterolateral humerus, deep to the deltoid, and inserting at the inferior portion of the posterior joint capsule. In 4 previously dissected and 17 distinct shoulders, intact LPNs could be identified in 14 (67%) of 21 specimens. Of these, 12 (86%) of 14 had articular branches innervating the anterior shoulder joint, and 14 (100%) of 14 LPN articular branches were adjacent to acromial branches of the thoracoacromial blood vessels over the superior aspect of the coracoid process.

**Conclusions:** Articular branches from the SN, AN, and LPN were identified. Articular branches of the SN and AN insert into the capsule overlying the glenohumeral joint posteriorly. Articular branches of the LPN exist and innervate a portion of the anterior shoulder joint.

(*Reg Anesth Pain Med* 2017;42: 564–570)

**P**ain of the shoulder, including the glenohumeral joint (GHJ),

The LPN has gained attention for chest wall and postmastectomy pain<sup>10</sup> but is underrecognized as a contributor to shoulder structures. Anatomical studies describe the LPN originating from C5–7 nerve roots, supplying innervation to the skin over the subacromial bursa,<sup>5,11</sup> muscular innervation of the pectoralis major and deltoid muscles,<sup>5</sup> and intra-articular innervation to the ACJ<sup>3,4</sup> and anterior GHJ.<sup>5,6,11</sup> Innervation of the ACJ and GHJ via articular branches of the LPN has potential for peripheral nerve blockade,<sup>5,6</sup> similar to AN and SN blocks.<sup>5–7</sup>

The AN originates from the posterior cord of the brachial plexus, dividing into anterior and posterior branches in the quadrangular space.<sup>12</sup> The nerve then innervates the deltoid muscle, teres minor muscle, shoulder joint capsule, and inferior GHJ, with its superior-lateral brachial cutaneous branch providing sensation over the deltoid muscle.<sup>12,13</sup> The AN is compelling for providing shoulder analgesia as demonstrated during preoperative blockade for upper-extremity surgeries.<sup>13</sup>

Originating from nerve roots C5–6, the SN branches off the superior trunk of the brachial plexus, coursing through the posterior triangle of the neck, and enters the suprascapular notch and spinoglenoid notch.<sup>14</sup> The nerve innervates the supraspinatus muscle and infraspinatus muscle and provides sensory input from the lateral upper extremity, GHJ, ACJ, subacromial bursa, coracohumeral ligament, and coracoacromial ligaments.<sup>15</sup> The SN is established as a target for shoulder analgesia in clinical practice.<sup>7,9,16,17</sup>

This study investigated the anatomic course of the SN, AN, and LPN to the GHJ in cadavers. We aimed to determine the location of terminal sensory articular branches of the shoulder and describe associations with bone, soft tissue, and vascular landmarks. Enhanced knowledge of terminal sensory nerve branches

**TABLE 1.** Summary of Literature Review for SN, AN, and LPN

Author and Year	Specimens	Sample Size, No. Shoulders	Articular Branch Innervation and Pathway
<b>SN</b>			
Aszmann et al, <sup>6</sup> 1996	Fresh-frozen adult cadavers	25	After entering suprascapular notch, the suprascapular nerve sends lateral articular branches to the coracoclavicular ligaments After giving off lateral articular branches to the coracoclavicular ligaments, the nerve then gives articular branches to the coracohumeral ligament, subacromial bursa, and posterior ACJ capsule. After giving a muscular branch to the suprascapular m., the suprascapular nerve gives lateral articular branches to the posterior joint capsule.
Ebraheim et al, <sup>18</sup> 2011	Embalmed adult cadavers	12	Articular branches came off the main suprascapular nerve after passing through the notch to innervate the ACJ and subacromial bursa.
Vorster et al, <sup>19</sup> 2008	Embalmed adult cadavers	31	After passing the suprascapular notch, the suprascapular nerve gives an articular branch which travels superolaterally around the base of the coracoid process then turns to run inferomedially toward the posterior shoulder capsule.
<b>AN</b>			
Aszmann et al, <sup>6</sup> 1996	Fresh-frozen adult cadavers	25	As AN crosses the subscapular muscle, it gives articular branch to inferior-anterior joint capsule
Gelber et al, <sup>20</sup> 2006	Fresh-frozen and embalmed adult cadavers	61	As AN passes through quadrangular space, it wraps laterally around humeral neck and pierces the deltoid, and then articular branches continue to pierce inferior glenohumeral ligament (13.11%). After AN passes through quadrangular space, articular branches arise from branch to teres minor (40.98%) or off main AN trunk (24.59%).
Nasu et al, <sup>21</sup> 2015	Embalmed adult cadavers	20	As AN passes through quadrangular space, it wraps laterally around humeral neck, pierces the deltoid, and then articular branches continue medially toward humerus, ascends humerus, pierces fascia, then continues to pierce subacromial bursa on lateral or anterolateral shoulder (60%). As AN leaves brachial plexus, articular branch pierces connective tissue of the long head of the biceps tendon (40%) and then pierces cortical bone of humerus at intertubercular sulcus (15%). As AN passes through quadrangular space, the main trunk gives articular branches to inferior joint capsule (75%), posterior joint capsule from teres minor branch (15%), and posterolateral long head of the triceps tendon from teres minor branch (15%).
<b>LPN</b>			
Akita et al, <sup>11</sup> 2002	Unspecified cadavers	125	The LPN gives an articular branch to the shoulder joint after passing over the acromion.
Aszmann et al, <sup>6</sup> 1996	Fresh-frozen adult cadavers	25	LPN sends articular branch to coracoclavicular ligament before piercing clavipectoral fascia. LPN passes between coracoacromial and coracoclavicular ligaments to innervate subacromial bursa and anterior acromioclavicular ligament.
Nam et al, <sup>5</sup> 2016	Unembalmed cadavers	43	LPN gives an articular branch along the superomedial margin of the deltoid muscle, along anterior coracoclavicular ligament, and then pierces the coracoacromial ligament to enter the shoulder joint (67.4%).

Each nerve has limited literature discussing sensory articular branches in human cadaveric models. Pathways of each nerve are described previously according to the authors.

and Anatomy and the body donation program. Thorough dissections were performed to confirm and add to the limited prior cadaveric studies<sup>5,6,11</sup> investigating the articular branches of the GHJ.

The cadaver was placed in prone (SN and AN) or supine (LPN) positioning, with both shoulders in internal rotation. All cadaver specimens were embalmed while in upper-extremity

internal rotation, preventing full passive range of motion of the shoulder into anatomical external rotation.

### Suprascapular Nerve

Sixteen shoulders (14 embalmed and 2 unembalmed) from 8 cadavers were examined for study of the SN. A coronal incision



was made along the superior border of the clavicle extending from its proximal origin to the first one-third of the shaft of the humerus. A second incision was made vertically extending from the proximal point of the first incision until halfway through the thorax, passing the inferior scapular angle. The third and final incision began at the inferior edge of the second incision, extending laterally to the midaxillary line and then connecting to the distal point of the first incision on the humeral shaft. The skin and superficial adipose layers were removed, exposing the entire scapula, axilla, and deltoid muscle.

The spine and medial border of the scapula were then palpated, and an incision was made along these 2 borders. The infraspinatus muscle was reflected toward its origin in the infraspinous fossa, with care taken not to disturb the neurovascular bundle innervating the infraspinatus muscle. The SN and suprascapular artery and vein were identified exiting the spinoglenoid notch.

### Axillary Nerve

Sixteen shoulders (14 embalmed and 2 unembalmed) from the same 8 cadavers used for the SN dissections were examined for study of the AN. A coronal incision was made along the distal tip of the acromion through one-third of the shaft of the humerus. The skin and superficial adipose layers were removed. The quadrangular space was identified, and excess adipose removed. The investigator exposed the AN and posterior circumflex humeral artery and vein exiting the quadrangular space. An incision was made along the superior origin of the deltoid muscle and was carefully reflected inferiorly without damaging the fascia between the deltoid muscle and head of the humerus.

### Lateral Pectoral Nerve

Twenty-one shoulders, all embalmed, from 11 cadavers were examined for study of the LPN. Four shoulders (2 cadavers) were shared from the SN/AN group, whereas the remaining 17 shoulders were supplied from 9 separate cadavers. Given increased delicacy of the LPN compared with SN and AN, more specimens were studied for LPN. With the cadaver supine, a coronal incision was made along the anterior aspect of the clavicle, beginning with its most proximal point and ending at the first one-third of the shaft of the humerus. A second incision was made vertically along the sternum, extending halfway down the thorax. Starting at the distal point of the second incision, a third transverse incision was made to extend laterally to the distal point of the first incision at the shaft of the humerus. The skin and superficial adipose layers were removed to expose the pectoralis major and minor muscles, deltoid muscle, clavicle, and axilla.

An incision was made along the sternum and inferior pectoralis major muscle to reflect the muscle superiorly, careful not to disturb the underlying structures. The medial pectoral nerve was identified piercing both pectoralis major and minor muscles, and then the LPN was identified piercing pectoralis major muscle. The LPN was traced back to its origin at the lateral cord of the brachial plexus.

### Part 3: Fluoroscopy

After dissections were completed, the investigators selected a cadaveric shoulder to be evaluated under fluoroscopy. Under fluoroscopy, anatomical landmarks, including the coracoid, acromion, humeral head, humeral neck, and glenoid fossa, were identified for needle placement. An 18-gauge aluminum wire was placed on the specimen, tracing the pathway of the SN, AN, and LPN to demonstrate relationships with nearby anatomic structures. The fluoroscopy system was positioned

in an anterior-posterior (LPN) or posterior-anterior (SN and AN) direction without any initial angular deviation in the medial, lateral, caudal, or cephalad direction. A series of fluoroscopic films were taken starting directly above the prone (SN and AN) or supine (LPN) cadaver (0 degrees) and proceeding at 5-degree increments until directly lateral to the humerus (90 degrees).

## RESULTS

### Cadaveric Dissection

#### Suprascapular Nerve

The SN was visualized in the spinoglenoid notch and identified innervating the supraspinatus and infraspinatus muscle. The main trunk of the SN gave articular branches superiorly and inferiorly to the spinoglenoid notch. Superiorly, these articular branches were seen along the supraspinous fossa of the spine of the scapula, coursing laterally toward the posterior GHJ and head of the humerus in all specimens. The nerves were then seen piercing the fascia overlying the head of the humerus (Figs. 1A and 2A). After the sensory nerves branched from the main trunk of SN superior to the spinoglenoid notch, no motor branches, other than the proximal motor branch innervating the supraspinatus muscle, were visualized. The SN displayed these anatomical pathways in 16 (100%) of 16 specimens.

As the SN passed inferiorly through the spinoglenoid notch, the main trunk proceeded medially to innervate the infraspinatus muscle, whereas the articular branches coursed laterally in the infraspinous fossa of the spine of the scapula toward the posterior inferior GHJ and head of the humerus. Terminal articular nerves were seen piercing the fascia overlying the head of the humerus in 100% of the specimens.

The suprascapular artery and vein were identified passing through the spinoglenoid notch. However, branches of the artery and vein did not appear to be associated with the terminal articular sensory branches described in the supraspinous and infraspinous fossae of the spine of the scapula. Rather, these vessels appeared to accompany the motor branches innervating the supraspinatus and infraspinatus mm.

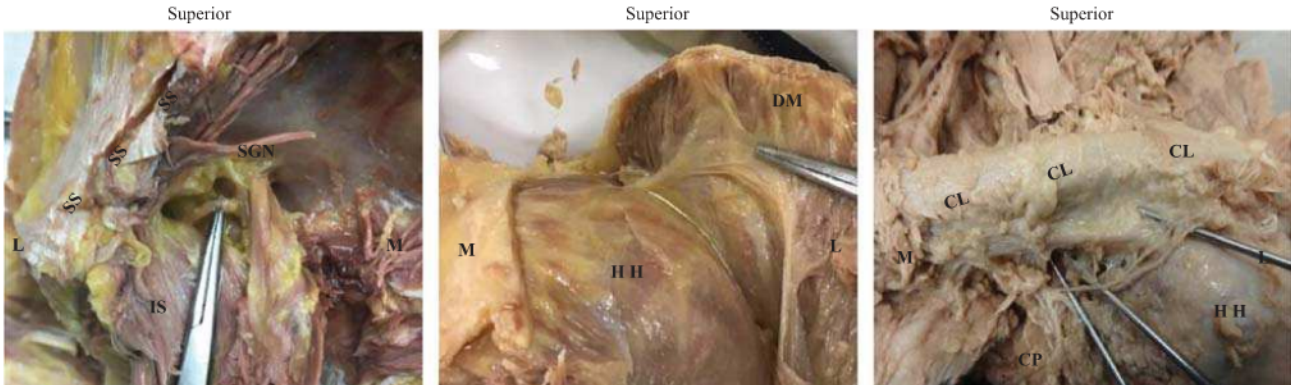
#### Axillary Nerve

After the AN was identified exiting the quadrangular space, its branches were followed until termination. Two motor branches came off the main trunk of the AN immediately distal to the quadrangular space and innervated the deltoid and teres minor muscle. The teres minor muscle branch appeared to have only motor innervation with all terminal branches piercing the muscle. The branch innervating the deltoid muscle coursed laterally around the head of the humerus, with the larger branch piercing the deltoid muscle adjacent to the lateral aspect of the humerus. Just proximally to the point of piercing the deltoid muscle, the larger branch gave off multiple smaller articular branches medially back toward the head of the humerus to innervate the posterior and lateral overlying fascia (Figs. 1B and 2B). These anatomic pathways were observed in 16 (100%) of 16 specimens.

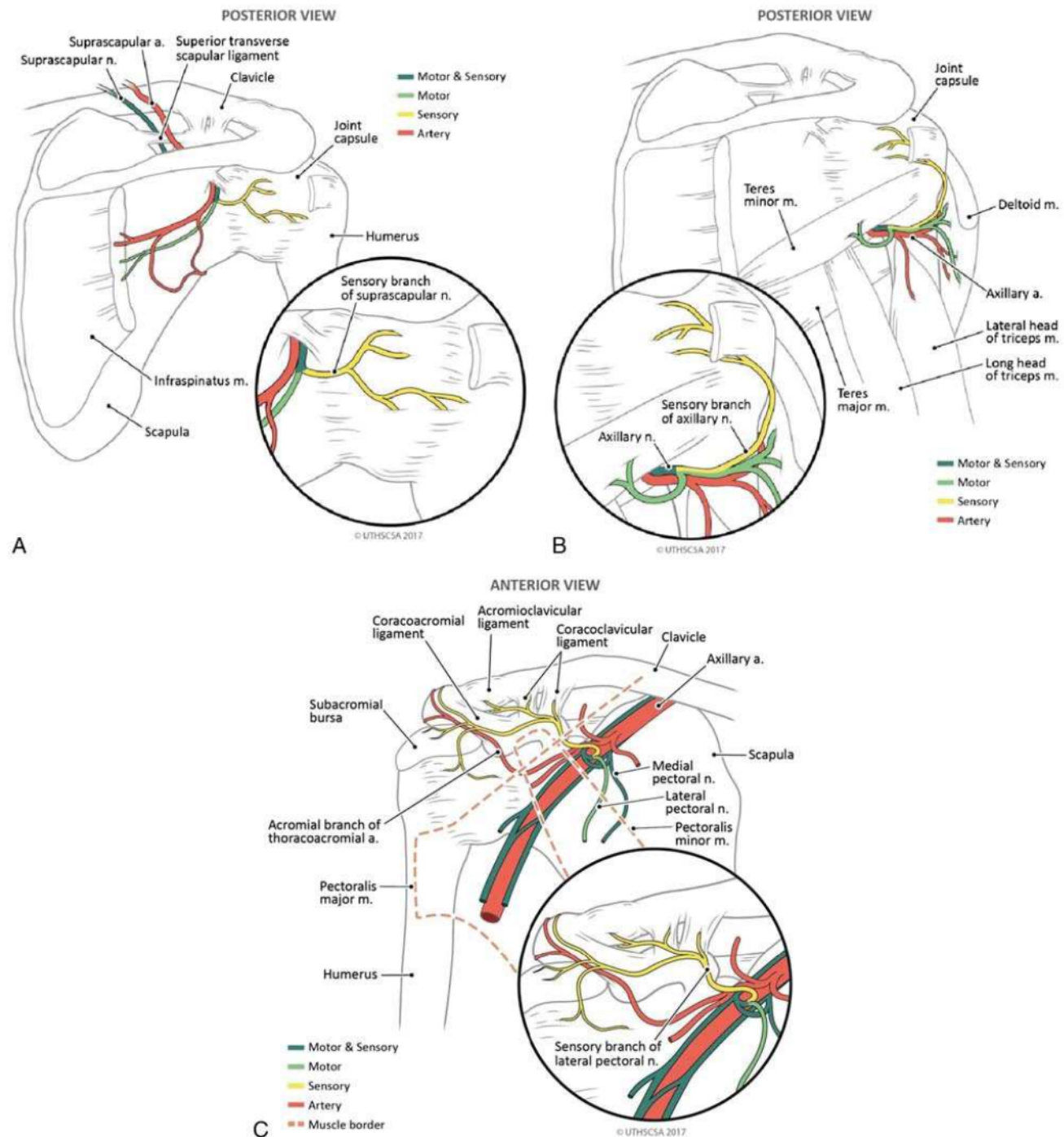
The posterior humeral circumflex artery and vein were identified in the quadrangular space next to the main trunk of the AN. However, the artery and vein did not accompany terminal articulating sensory branches in any of the specimens.

#### Lateral Pectoral Nerve

Twenty-one intact shoulder girdles were evaluated for suitability of dissection. In 14 of these, tissue integrity was amenable to identification of the LPN. In 12 (86%) of these 14 shoulder







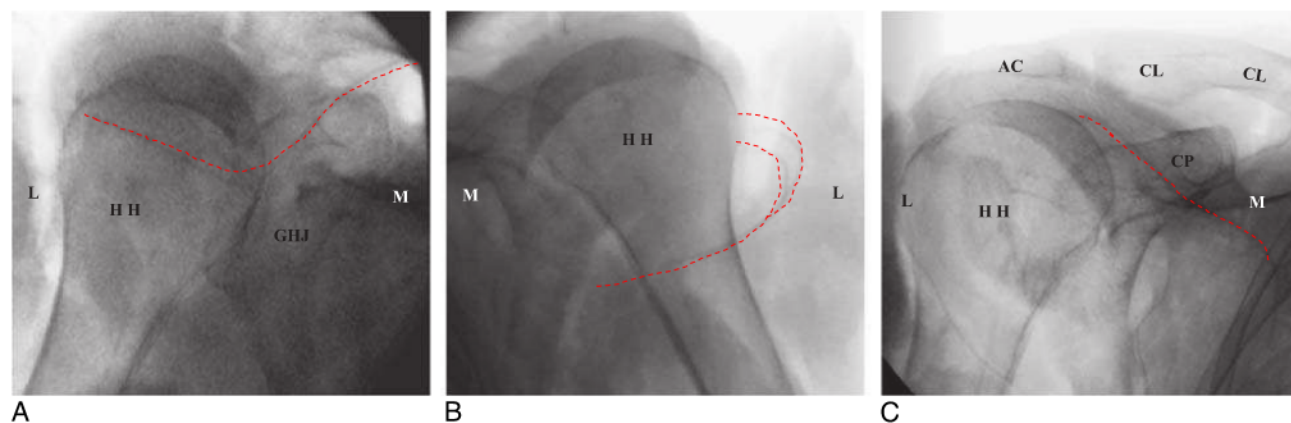
**FIGURE 2.** Medical illustrations depicting the anatomic course of SN (A), AN (B), and LPN (C). A, The SN exiting the spinoglenoid notch. A motor branch immediately innervates infraspinatus, whereas the sensory branch travels laterally in the infraspinous fossa to innervate the humeral head and shoulder capsule. B, The AN exiting the quadrangular space, wrapping laterally to innervate the deltoid muscle and then continuing to provide pure sensory innervation to the posterior-lateral humeral head and shoulder capsule. C, The LPN branching from the upper trunk of the brachial plexus to innervate the pectoralis major muscle with a motor branch. A pure sensory branch of LPN then continues superior to the acromial branch of the thoracoacromial artery to innervate the anterior superior GHJ and coracoacromial ligament.

glenoid fossa, acromion, humeral head, and humeral neck allow for reliable identification of these zones.

### Axillary Nerve

This study identified terminal articular branches of the AN in all 16 shoulder specimens studied. In all specimens, the AN gave

terminal articular branches distal to teres minor and deltoid motor branches. These terminal articular branches were oriented in an inferior-superior (teres minor muscle) or lateral-medial (deltoid muscle) direction to innervate the fascia of the humeral head and neck, inferior GHJ, and inferior-posterior shoulder joint capsule in all specimens. This anatomic pattern is similar to previous



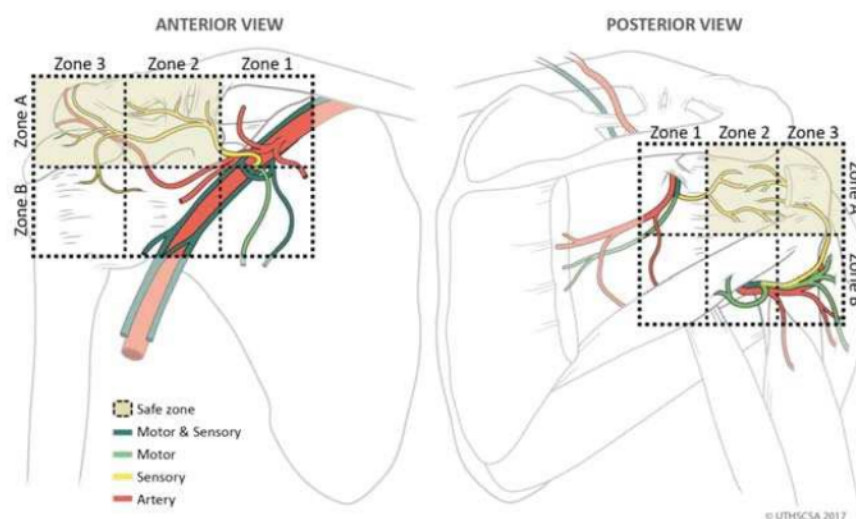
**FIGURE 3.** Fluoroscopy photographs of SN (A), AN (B), and LPN (C). A, Left shoulder, prone positioning. The sensory articular branches of SN travel laterally after exiting spinoglenoid notch and innervating the posterior shoulder capsule. The HH and GHJ are clearly seen under fluoroscopy. B, Right shoulder, prone positioning. The sensory articular branches of AN branch from the main AN trunk after providing motor innervation to the deltoid and then travel medially toward the HH. HH is clearly seen under fluoroscopy. C, Right shoulder, supine positioning. The LPN articular branches travel laterally inferior to the AC and CL and lateral to CP. CP, CL, AC, and HH are clearly seen under fluoroscopy. HH, humeral head; CL, clavicle; L, lateral; M, medial; CP, coracoid process; AC, acromion process.

studies,<sup>20,21</sup> but with more consistency. In addition, this study evaluated motor branches of the AN and their relationship to the pure sensory articular branches. In all specimens, the terminal articular branches provided pure sensory innervation and did not have any motor contributions. These sensory fibers were in clearly distinct anatomic regions, zones 2A and 3A, compared with their proximal motor counterparts, zones 1B and 2B (Fig. 4).

This study confirmed the existence of these terminal sensory articular branches of AN. The investigation of the anatomic relationship between sensory articular branches and motor branches of the AN was previously not described. The glenoid fossa, acromion, humeral head, and humeral neck would be ideal anatomic landmarks in fluoroscopy examinations as demonstrated in this study.

### Lateral Pectoral Nerve

The anatomic course of the articular branches described in this study was similar to that in the study of Aszmann et al<sup>6</sup> and is summarized in Table 1. Further studies could focus on ability to identify acromial and possibly deltoid branches of the thoracoacromial artery with ultrasound and using those vessels as an anatomic reference to find and block the articular branches of LPN to the shoulder joint. The LPN articular branch appears to have a branch to the clavicle, acromion joint, subacromial bursa, and occasional muscular branch to the deltoid. The LPN may have another branch, often separate from the articular branch, innervating the subclavius muscle. Statistical analysis of these LPN branches and variants was beyond the scope of this study.



**FIGURE 4.** Medical illustrations depicting anatomic safe zones. Anterior view: zones 1 and 2 are bisected by the proximal end of the coracoid process. Zones 2 and 3 are bisected by the distal end of the coracoid process. Zones A and B are bisected by the inferior border of the coracoid process. Possible safe zones for sensory branch intervention are 2A and 3A. Posterior view: zones 1 and 2 are bisected by the GHJ. Zones 2 and 3 are bisected by the medial-lateral plane of the humeral head. Zones A and B are bisected by the inferior pole of the GHJ and the surgical head of the humerus. Zones 2A and 3A are possible safe areas for sensory branch intervention.



The LPN articular branches in the anterior view are located in zones 2A and 3A as seen in Figure 4. Relevant landmarks are the acromion, coracoid process, GHJ, and acromial branch of thoracoacromial artery. In agreement with findings by Nam et al,<sup>5</sup> the superior and distal aspect of the coracoid process appears to be a reasonable area to target the pure sensory portions of the LPN.

## CONCLUSIONS

This cadaveric study confirmed prior studies' results, which showed existence of SN, AN, and LPN articular branches. Suprascapular nerve sends additional articular branches posteriorly from a medial-lateral direction over the head of the humerus. Axillary nerve posteriorly sends articular branches from an inferior-superior and lateral-medial direction. The LPN branches course in a superior-lateral direction adjacent to thoracoacromial vessels across the superior aspect of the coracoid process and then descends into the anterior-superior GHJ.

Limitations to this study include small sample size and diminished tissue integrity in a few specimens (LPN group). Larger cadaveric studies investigating the full length of the nerves' origin, variations, and commonality of branches to the subacromial region, deltoid muscle, ACJ, and GHJ should be undertaken. Validation and clinical prospective study are needed to establish the precision, safety, and effectiveness of SN, AN, and LPN articular blockade for shoulder pain.

## ACKNOWLEDGMENTS

The authors thank Robert Chalk and the Anatomical Services staff of the Body Donation Program of the Department of Cell Systems and Anatomy and the Anesthesia Department for their continued support and assistance with providing materials and staff for assistance of this study. The authors also thank the individuals who donate their bodies and tissues for the advancement of education and research.

## REFERENCES

- Andrews JR. Diagnosis and treatment of chronic painful shoulder: review of nonsurgical interventions. *Arthroscopy*. 2005;21:333–347.
- Adey-Wakeling Z, Arima H, Crotty M, et al. Incidence and associations of hemiplegic shoulder pain poststroke: prospective population-based study. *Arch Phys Med Rehabil*. 2015;96:241–247.
- Silvestri J. Effects of chronic shoulder pain on quality of life and occupational engagement in the population with chronic spinal cord injury: preparing for the best outcomes with occupational therapy. *Disabil Rehabil*. 2017;39:82–90.
- Van der Windt D, Koes BT, de Jong BA, Bouter LM. Shoulder disorders in general practice: incidence, patient characteristics, and management. *Ann Rheum Dis*. 1995;54:959–964.
- Nam YS, Panchal K, Kim IB, Ji JH, Park MG, Park SR. Anatomical study of the articular branch of the lateral pectoral nerve to the shoulder joint. *Knee Surg Sports Traumatol Arthrosc*. 2016;24:3820–3827.
- Aszmann OC, Dellon AL, Birely BT, McFarland EG. Innervation of the human shoulder joint and its implications for surgery. *Clin Orthop Relat Res*. 1996;330:202–207.
- Klç Z, Filiz MB, Çakır T, Toraman NF. Addition of suprascapular nerve block to a physical therapy program produces an extra benefit to adhesive capsulitis: a randomized controlled trial. *Am J Phys Med Rehabil*. 2015;94:912–920.
- Kim JS, Nahm FS, Choi EJ, Lee PB, Lee GY. Pulsed radiofrequency lesioning of the axillary and suprascapular nerve in calcific tendinitis. *Korean J Pain*. 2012;25:60–64.
- Tran DQ, Elgueta MF, Aliste J, Finlayson RJ. Diaphragm-sparing nerve blocks for shoulder surgery. *Reg Anesth Pain Med*. 2017;42:32–38.
- Bouzinac A, Tournier JJ, Delbos A, Bérot JE. Interest of ultrasound-guided lateral pectoral nerve block associated with paravertebral block for complete mastectomy pain management [in French]. *Ann Fr Anesth Reanim*. 2014;33:548–550.
- Akita K, Kawashima T, Shimokawa T, Sato K, Sato T. Cutaneous nerve to the subacromial region originating from the lateral pectoral nerve. *Ann Anat*. 2002;184:15–19.
- Gurushantappa PK, Kuppasad S. Anatomy of axillary nerve and its clinical importance: a cadaveric study. *J Clin Diagn Res*. 2015;9:AC13–AC17.
- Ball CM, Steger T, Galatz LM, Yamaguchi K. The posterior branch of the axillary nerve: an anatomic study. *J Bone Joint Surg Am*. 2003;85-A:1497–1501.
- Yang HJ, Gil YC, Jin JD, Ahn SV, Lee HY. Topographical anatomy of the suprascapular nerve and vessels at the suprascapular notch. *Clin Anat*. 2012;25:359–365.
- Cummings CA, Messer TM, Nuber GW. Suprascapular nerve entrapment. *J Bone Joint Surg Am*. 2000;82:415–424.
- Mortada MA, Ezzeldin N, Abbas SF, Ammar HA, Salama NA. Multiple versus single ultrasound guided suprascapular nerve block in treatment of frozen shoulder in diabetic patients. *J Back Musculoskelet Rehabil*. 2017;30:537–542.
- Chan CW, Peng PW. Suprascapular nerve block: a narrative review. *Reg Anesth Pain Med*. 2011;36:358–373.
- Ebraheim NA, Whitehead JL, Alla SR, et al. The suprascapular nerve and its articular branch to the acromioclavicular joint: an anatomic study. *J Shoulder Elbow Surg*. 2011;20:e13–e17.
- Vorster W, Lange CP, Briët RJ, et al. The sensory branch distribution of the suprascapular nerve: an anatomic study. *J Shoulder Elbow Surg*. 2008;17:500–502.
- Gelber PE, Reina F, Monllau JC, Yema P, Rodriguez A, Caceres E. Innervation patterns of the inferior glenohumeral ligament: anatomical and biomechanical relevance. *Clin Anat*. 2006;19:304–311.
- Nasu H, Nimura A, Yamaguchi K, Akita K. Distribution of the axillary nerve to the subacromial bursa and the area around the long head of the biceps tendon. *Knee Surg Sports Traumatol Arthrosc*. 2015;23:2651–2657.