

# Nerve-root injections for the relief of pain in patients with osteoporotic vertebral fractures

Don-Jun Kim, Yeo-Hon Yun, Jin-Man Wang

From the Ewha Womans University Hospital and the Ewha Medical Research Centre, Seoul, Korea

**We have studied 58 patients with pain from osteoporotic vertebral fractures which did not respond to conservative treatment. These were 53 women and five men with a mean age of 72.5 years. They received a nerve-root injection with lidocaine, bupivacaine and DepoMedrol. The mean follow-up period was 13.5 months.**

**The mean pain scores before treatment, at one and six months after treatment and at the final follow-up were 85, 24.9, 14.1, and 17.4, respectively. According to our modified criteria for grading results, six patients were considered to have an excellent result, 42 good and ten fair. A newly developed compression fracture was noted in three patients. There were no complications related to the injection.**

**Our study suggests that nerve-root injections are effective in reducing pain in patients with osteoporotic vertebral fractures and that these patients should be considered for this treatment before percutaneous vertebroplasty or operative intervention is attempted.**

*J Bone Joint Surg [Br]* 2003;85-B:250-3.

Received 4 March 2002; Accepted 12 July 2002

Vertebral fracture is a common complication of osteoporosis and causes significant disability. Although most fractures heal within a few weeks or months, some do not respond to conservative treatment. Surgery is usually not indicated unless there is a neurological deficit or gross deformity.<sup>1,2</sup>

Vertebroplasty by the percutaneous injection of polymethylmethacrylate (PMMA) into the vertebral bodies has been proposed for the augmentation of osteoporotic vertebral bodies. The technique is easy to do and gives immedi-

ate good mechanical results.<sup>3,4</sup> Significant relief from pain is obtained in most patients. The potential complications of this technique include cell death caused by the high polymerisation temperature of PMMA, differences in mechanical strength of the injected compared with the adjacent vertebral bodies, and leakage of PMMA into adjacent structures. Moreover, the long-term biocompatibility of PMMA is jeopardised by its presence as a permanent implant. Vertebroplasty has an important place in the treatment of osteoporotic vertebral fractures but there are many patients who require a less invasive method.

The epidural injection of steroids is a popular method of treatment for lumbar radiculopathy,<sup>5-9</sup> but injections at the thoracic or thoracolumbar levels may be associated with neurological complications. Nerve-root injections offer an alternative form of treatment. Since Macnab<sup>10</sup> described the technique in 1971, numerous authors have reported its effect on radicular pain.<sup>10-15</sup> Krempen and Smith<sup>11</sup> coined the term 'selective nerve root injection' which various investigators have used diagnostically or to predict the outcome of surgery. Recently, Riew et al<sup>15</sup> have described the therapeutic efficacy of nerve-root injections in a prospective study of patients with radiculopathy secondary to herniation of an intervertebral disc or spinal stenosis. To our knowledge, however, there has been no previous clinical study evaluating its efficacy in the management of radicular pain secondary to vertebral fractures.

## Patients and Methods

Between October 1998 and October 2000, all 66 patients who presented with osteoporotic vertebral fractures and radicular pain which did not respond to conservative treatment were included in the study (Fig. 1). The exclusion criteria were axial pain without radicular pain, a progressive neurological deficit, a motor deficit, and a history of an adverse reaction to corticosteroids or local anaesthetic agents and follow-up of less than one year. All the patients who were included had completed a course of conservative treatment. Patients with acute fractures in whom the symptoms had been present for less than two weeks were treated by bed rest for three days followed by bracing for four weeks. Those with chronic fractures were treated by intermittent bracing. Analgesics consisting of oral non-steroidal

D-J. Kim, MD, Associate Professor  
Y-H. Yun, MD, Associate Professor  
J-M. Wang, MD, Professor and Director  
Department of Orthopaedic Surgery, Ewha Medical Research Centre, Ewha Womans University Hospital, 70 Chongro 6 Ka, Chongro Ku, Seoul 110-126, Korea.

Correspondence should be sent to Dr D-J. Kim.

©2003 British Editorial Society of Bone and Joint Surgery  
doi:10.1302/0301-620X.85B2.13289 \$2.00

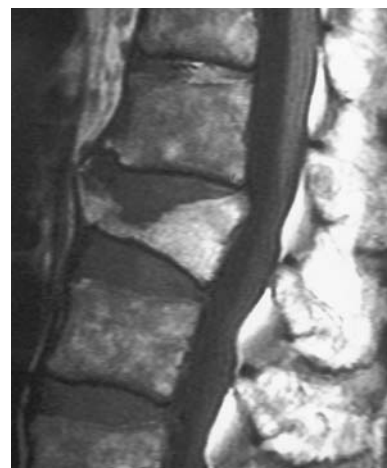
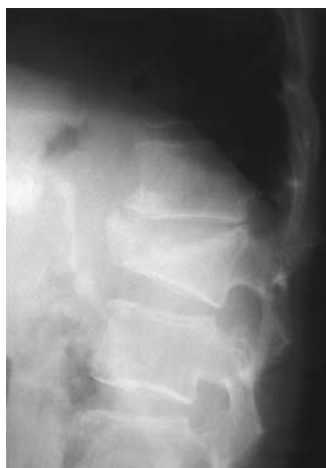
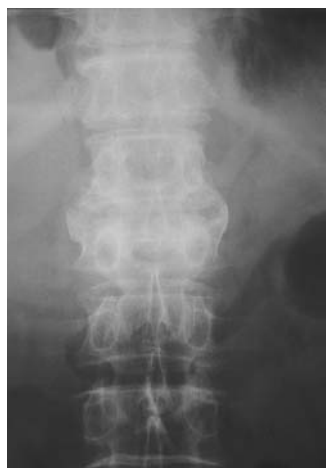Fig. 1a

Fig. 1b

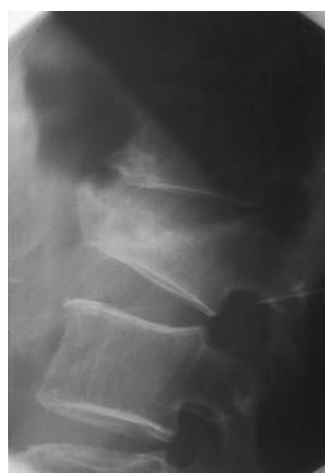
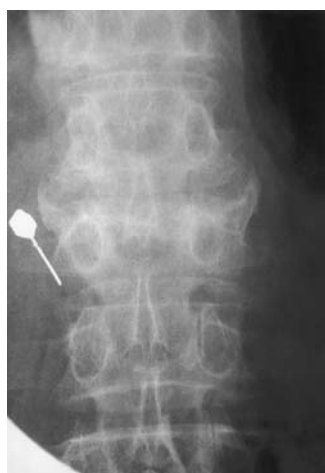
Fig. 1c

A 75-year-old woman had severe pain in the right loin and lower abdomen. Fig. 1a – Plain radiographs showing an old fracture of the second lumbar spine. Fig. 1b – MRI showing old healed fracture with slight retropulsion of the upper bony fragment. Fig. 1c – Radiographs showing an injection of the second lumbar nerve root with a 20-gauge spinal needle. The tip of the needle is seen advancing to the centre of the neural foramen.

anti-inflammatory drugs and acetaminophen were administered to both groups. Conservative treatment was considered to have failed when severe pain continued despite treatment for two weeks or when the pain did not improve after treatment for more than four weeks.

Eight patients were lost to follow-up, leaving 58 in the study. They were 53 women and five men, with a mean age of 72.5 years (65 to 82). Nine patients had another painful vertebral fracture and thus the number of fractures was 67. The 12th thoracic vertebra was the most commonly involved (28 fractures), followed by the first lumbar (23), the 11th thoracic (8) and the second lumbar (4). There was one each in the sixth, eighth, ninth, and tenth thoracic vertebrae. Of the 58 patients 42 had chronic and 16 acute fractures. Of the nine patients with another painful vertebral fracture, six already had two chronic painful fractured vertebrae at the time of presentation, and in three patients the second fracture occurred during the follow-up period.

**Method of injection.** The procedure was carried out with the aid of an image intensifier. The patient was placed in the prone position and the back prepared in the usual manner. In order to localise the site of entry, the tip of a sterile haemostat was placed at the point of intersection between the lateral margin of the lamina and the inferior margin of the transverse process (Fig. 2). The site of entry was marked with indelible ink and the skin infiltrated with 1% lidocaine. A 20-gauge, 13 cm spinal needle was inserted under fluoroscopic guidance into the selected intervertebral foramen. The patient usually experienced a sharp stab of radiating pain when the nerve root was found. Once it had been determined that this pain reproduced the symptoms, a mixture of 0.5 ml of 2% lidocaine, 0.5 ml of 0.5% bupivacaine and 40 mg (1ml) of DepoMedrol was injected.

For the patients with two lesions or whose radiating pain was bilateral, all injections were done at the same time, with a maximum of four being carried out simultaneously. For

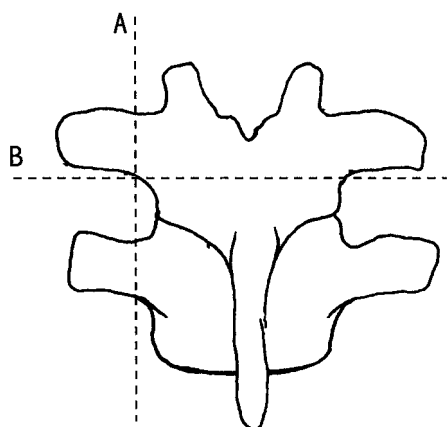


Fig. 2

Diagram showing an entry point crossing a vertical line just lateral to the pars interarticularis (A) and a horizontal line just distal to the transverse process (B).

**Table I.** Modified criteria of Kim and Kim<sup>16</sup> for grading clinical results

Grade	
Excellent	Complete relief from pain No limitation of physical activity Analgesics not used
Good	Relief from most pain Physical activities slightly limited Analgesics used infrequently
Fair	Partial relief from pain Physical activities definitely limited Analgesics used frequently
Poor	Little or no relief from pain Physical activities greatly limited Analgesics used regularly

more than three injections, the total amount of DepoMedrol was adjusted in order not to exceed 100 mg. The procedure was repeated at two-week intervals to a maximum of three or until there was symptomatic improvement.

**Follow-up observation and evaluation.** One of the authors (YHY), who was not involved in their management, examined the patients before treatment, at one and six months after the last injection and at the final follow-up. At each examination, the patients were asked to record their daily pain on a scale of 0 to 100, with 0 being no pain and 100 being intolerable pain. Final follow-up evaluations were carried out at a mean of 14 months (12 to 19) after the last injection. At the final follow-up, the result was graded using the modified criteria of Kim and Kim<sup>16</sup> (Table I). We stratified the data further to compare the results for patients with acute and those with chronic fractures.

## Results

**Changes in pain scales.** Before treatment, the mean pain score was  $85 \pm 6.7$  (70 to 90), 84.0 in the acute group and

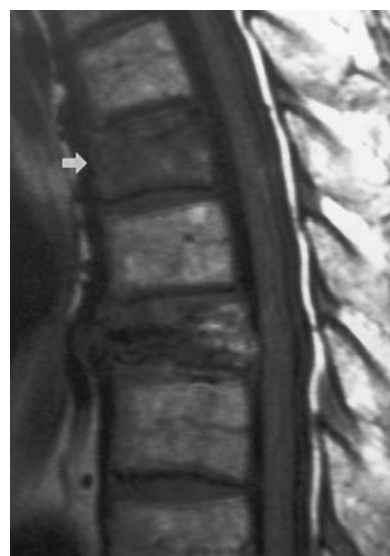

Fig. 3

MRI of 71-year-old man showing an additional fracture of the sixth thoracic vertebra (white arrow) two levels above the previous fracture.

**Table II.** Clinical results at final follow-up after a nerve-root injection for the relief of pain in patients with osteoporotic vertebral fractures, by number and *percentage*

Grade	Acute fracture	Chronic fracture	Total
Excellent	3 (18.8)	0	3 (5.2)
Good	10 (62.5)	31 (73.8)	41 (70.7)
Fair	3 (18.8)	11 (26.2)	14 (24.1)
Poor	0	0	0
Total	16 (100.0)	42 (100.0)	58 (100.0)

85.5 in the chronic group. The mean score after one month was  $24 \pm 10.6$  (10 to 45), with a decrease of about 60.1. The mean score for patients with chronic fractures was  $21.3 \pm 9.3$  and for those with acute fractures  $32.2 \pm 9.7$ . The improvement was greater in patients with chronic fractures ( $p < 0.05$ ). The mean score six months after treatment was  $14.1 \pm 3.5$  (10 to 21) with no significant difference between chronic and acute fractures (14.3 and 13.4, respectively). At the final follow-up, the mean score was  $17.4 \pm 7.5$  (5 to 35), a slight increase from that at six months, but with an improvement of about 67.6 compared with the score before treatment. The mean score for chronic fractures was  $18.3 \pm 7.5$  and for acute fractures  $15.7 \pm 7.9$ . There was no significant difference in the mean scores between the two groups at the final follow-up.

**Clinical results.** The results at final follow-up were excellent in three patients, good in 41 and fair in 14 (Table II). The three with excellent results all had chronic fractures. Of the 14 patients with fair results, 11 had chronic fractures.

**Number of injections.** A total of 14 patients had one injection, 30 had two (18 at the same time and 12 separately),

seven had three injections in two treatments, five had four injections in two treatments, one had six injections in three treatments and one had eight injections in two treatments.

**Complications.** There were no complications directly related to treatment. Three patients developed a new compression fracture at an additional level during the follow-up period. The new fracture was at a proximal level in all three patients and it was at an adjacent level in two of them. Pain experienced at the site of the new fracture was usually distinct from the original pain. It was difficult to recognise a newly developed fracture of the upper thoracic spine. For instance, a 71-year-old man who had a fracture of the eighth thoracic vertebra was improving after nerve-root injections, but about three months after treatment the pain recurred. He received another nerve-root injection at the same level, without improvement. MRI showed a new fracture of the sixth thoracic vertebra (Fig. 3). The symptoms improved after a nerve root injection at this level.

## Discussion

Riew et al<sup>15</sup> carried out a prospective study on the therapeutic efficacy of nerve-root injections for patients with radicular pain caused by herniation of a disc or spinal stenosis. They found that the injections were effective in obviating the need for an operation in more than half of the patients in whom surgery had been proposed. Our study on patients with fractures also shows varying degrees of symptomatic improvement with 44 patients (75.9%) achieving excellent or good results. This is an acceptable outcome, bearing in mind that the mean age of the patients was 72.5 years. We divided the patients into those with chronic and those with acute fractures and found that the former had a greater improvement in the pain score one month after treatment but that there was no significant difference at final follow-up. There was greater overall improvement in patients with acute fractures. They had higher pain scores after one month, but better results at the final follow-up. We suggest that this is due to the residual effect of the axial pain which is caused by acute fractures.

When undertaking nerve-root injection for fractures it is important to avoid injecting too much steroid. If two vertebrae are fractured and there is bilateral radiating pain the procedure involves four injections using 40 mg of DepoMedrol per injection giving a total dose of 160 mg. We did not exceed a total dose of 100 mg of DepoMedrol in one session even when more than three injections were required. Patients received up to three injections with an interval of two weeks between treatments.

There were no complications directly related to the treatment. Three patients, however, developed a new compression fracture at another level. Fractures in adjacent vertebrae

may occur after vertebroplasty because of local biomechanical changes. The pain from a new fracture can usually be differentiated from the original pain. It was sometimes difficult to recognise the newly developed fracture in patients with an upper thoracic lesion. This study was, however, limited to patients with radicular pain. Several also complained of axial pain and there was some improvement in this after nerve-root injection.

In conclusion we have shown that nerve-root injections are effective in the treatment of pain resulting from osteoporotic vertebral fractures. This treatment should be considered for patients who have refractory pain from vertebral fractures before consideration is given to percutaneous vertebroplasty or operative intervention.

No benefits in any form have been received or will be received from a commercial party related directly or indirectly to the subject of this article.

## References

1. Hasegawa K, Homma T, Uchiyama S, Takahashi H. Vertebral pseudoarthrosis in the osteoporotic spine. *Spine* 1998;23:2201-6.
2. Kaneda K, Asano S, Hashimoto T, Satoh S, Fujiya M. The treatment of osteoporotic-posttraumatic vertebral collapse using the Kaneda device and a bioactive ceramic vertebral prosthesis. *Spine* 1992; 17 (8 Suppl):295-303.
3. Barr JD, Barr MS, Lemley TJ, McCann RM. Percutaneous vertebroplasty for pain relief and spinal stabilization. *Spine* 2000;25:923-8.
4. Belkoff SM, Mathis JM, Erbe EM, Fenton DC. Biomechanical evaluation of a new bone cement for use in vertebroplasty. *Spine* 2000;25:1061-4.
5. Berman AT, Garbarino JL Jr, Fisher SM, Bosacco SJ. The effects of epidural injection of local anaesthetics and corticosteroids on patients with lumbosacral pain. *Clin Orthop* 1984;188:144-51.
6. Cuckler JM, Bernini PA, Wiesel SW, et al. The use of epidural steroids in the treatment of lumbar radicular pain: prospective, randomised, double-blind study. *J Bone Joint Surg [Am]* 1985;67-A:63-6.
7. Bush K, Hillier S. A controlled study of caudal epidural injections of tramadolone plus procaine for the management of intractable sciatica. *Spine* 1991;16:572-5.
8. Bogduk N. Spine update: epidural steroids. *Spine* 1995;20:845-8.
9. Koes BW, Scholten RJ, Mens JM, Bouter LM. Efficacy of epidural steroid injections for low-back pain and sciatica: a systemic review of randomised clinical trials. *Pain* 1995;63:279-88.
10. Macnab I. Negative disc exploration. An analysis of the cause of nerve root involvement in sixty-eight patients. *J Bone Joint Surg [Am]* 1971;53-A:891-903.
11. Krempen JF, Smith BS. Nerve-root injection. A method of evaluating the etiology of sciatica. *J Bone Joint Surg [Am]* 1974;56-A:1435-44.
12. Tajima T, Furukawa K, Kuromochi E. Selective lumbosacral radiculography and block. *Spine* 1980;5:68-7.
13. Stanley D, McLaren MI, Euinton HA, Getty CJ. A prospective study of nerve root infiltration in the diagnosis of sciatica: a comparison with radiculography, computed tomography and operative findings. *Spine* 1990;15:540-3.
14. Derby R, Kine G, Saal JA, et al. Response to steroid and duration of radicular pain as predictors of surgical outcome. *Spine* 1992;17 (6 Suppl):176-83.
15. Riew KD, Yin Y, Gilula L, et al. The effect of nerve-root injections on the need for operative treatment of lumbar radicular pain: a prospective, randomised, controlled, double-blinded study. *J Bone Joint Surg [Am]* 2000;82-A:1589-93.
16. Kim NH, Kim DJ. Anterior interbody fusion for spondylolisthesis. *Orthopaedics* 1991;14:1069-76.