

SPINE SECTION

Original Research Article

Anticoagulant and Antiplatelet Management for Spinal Procedures: A Prospective, Descriptive Study and Interpretation of Guidelines

Bradly S. Goodman, MD,* L. McLean House, MD,[†] Sridhar Vallabhaneni, MD,[‡] Srinivas Mallempati, MD,* Matthew R. Willey, MD,[§] and Matthew Thomas Smith, MD[¶]

*Alabama Ortho Spine & Sports, Birmingham, Alabama; [†]Department of Anesthesia and Perioperative Care, University of California, San Francisco, California; [‡]Advanced Pain and Anesthesia Consultants, Crown Point, Indiana; [§]Orlando Orthopaedic Center, Orlando, Florida; [¶]Alabama Pain Physicians, Vestavia Hills, Alabama, USA

Correspondence to: Bradly S. Goodman, MD, Alabama Ortho Spine & Sports, 1801 Gadsden Hwy, Birmingham, AL 35235, USA. Tel: 205-838-3900; Fax: 205-838-3906; E-mail: drspudhead@aol.com

Funding sources: Authors received no funding for this endeavor.

Disclosure and conflicts of interest: Dr. Goodman, Dr. House, Dr. Vallabhaneni, Dr. Mallempati, Dr. Willey, and Dr. Smith have no conflicts of interest to report. They have not received any reimbursement or honoraria in any other manner.

Abstract

Setting. Epidural hematoma rarely complicates interventional spine procedures. While anticoagulant and antiplatelet drugs increase bleeding risk, cessation may precipitate serious thromboembolic events. The Spine Intervention Society (SIS) and American Society of Regional Anesthesia and Pain Medicine (ASRA) put forth guidelines that dissent with regard to management of hemostatically active agents during commonly performed spinal injections.

Objective. To validate an antiplatelet/anticoagulant management table based on modifications of the SIS 2013 and ASRA 2015 guidelines.

Design. Prospective descriptive study.

Subjects. Patients undergoing interventional spine injections from an interventional physiatrist's practice.

Methods. A Modified SIS 2013—ASRA 2015 Antiplatelet & Anticoagulant (MSAAA) guideline table was devised and adopted. Patients undergoing interventional spine procedures were monitored for bleeding events.

Results. Of 4,253 injection sites, 197 (4.6%) were performed in 74 patients on antiplatelet/anticoagulants. No clinically evident bleeding events were observed in patients on antiplatelet/anticoagulant medications for lumbar transforaminal epidural (N = 90), posterior-approach facet joint (N = 62), lumbar intradiscal (N = 11), lumbar sympathetic (N = 3), and sacroiliac (N = 5) injections or in 26 radiofrequency neurotomy procedures. One in 2,026 (0.05%, 95% confidence interval = 0.00–0.31%) interlaminar epidural injections (cervical, thoracic, lumbar, and caudal) suffered epidural hematoma. This patient was not on an antiplatelet/anticoagulant drug. No patient in 191 cervicothoracic and 723 lumbar transforaminal injections experienced bleeding complications.

Conclusions. Continuing antiplatelet and anticoagulant medications for intermediate- to low-risk interventional spine procedures may be advisable. The MSAAA table may be a reasonable guideline reference for managing antiplatelet and anticoagulant drugs.

Key Words. Epidural (injection space); Facet Joint; Outcome Assessment; Pain Medicine; Transforaminal Epidural Injection; Antiplatelet; Anticoagulant

Introduction

Epidural injection of corticosteroids and local anesthetics relieve radicular pain [1,2]. However, epidural

hematoma may complicate these elective procedures. As hematomas expand, they compress spinal nerve roots and the central cord, manifesting as pain, paresthesia, urinary retention, paresis, and paralysis [3].

Periprocedural management of anticoagulation and antiplatelet medications has undergone substantial revision. Only recently has the first randomized, placebo-controlled trial investigating perioperative bridging in atrial fibrillation patients been reported [4]. Risk of bleeding must be balanced against the chance of thromboembolic events associated with agent discontinuation [5]. During interventional spine and neuraxial anesthesia, bleeding risk while continuing antiplatelet or anticoagulant drugs during epidural catheterization may be three-fold greater than if discontinued [6,7]. However, risk of bleeding for spinal injection may be less than for catheter-based neuraxial anesthesia.

Spinal injection encompasses myriad interventions, the individual bleeding risks of which are uncertain. The Spine Intervention Society (SIS, formerly the International Spine Intervention Society) published guidelines presenting procedure-specific risks in 2013 [6]. The American Society of Regional Anesthesia and Pain Medicine (ASRA) later rated some of the most commonly performed spinal injections, including interlaminar epidural, transforaminal epidural, facet (zygapophyseal) joint, sympathetic block, radiofrequency neurotomy, and lumbar intradiscal injections as “intermediate risk” for bleeding complications [8]. This rating was contrary to SIS guidelines, which suggested that lumbar (L₁–L₅) transforaminal epidural, posterior-approach facet joint, radiofrequency neurotomy, sacroiliac, lumbar sympathetic, lumbar intradiscal injections may be safely performed while continuing certain blood-thinning agents.

This study aimed to clarify the risk of epidural hematoma following commonly performed spinal injections. We present the Modified SIS 2013—ASRA 2015 Anticoagulant and Antiplatelet (MSAAA) guideline table for agent continuation or cessation during interventional spine procedures. This table was implemented to guide management, and interventions where antiplatelet and anticoagulant agents were continued were tabulated by procedure and agent.

Methods

Waiver of informed consent was obtained from the institutional review board. The authors developed the MSAAA guideline table (Table 1) to direct antiplatelet/anticoagulant continuation or cessation during interventional spine procedures. The study period took place from February 1, 2015, to June 7, 2016. We gathered procedure and medication data from a single interventional physiatrist’s practice through current procedural terminology (CPT) codes and electronic medical records. International normalized ratio (INR) was gathered for patient continuing warfarin therapy. Injections in patients for whom antiplatelet and anticoagulant medications were continued were tabulated by injection type and by

medication. The following agents were identified from patient records: warfarin (Coumadin or Jantoven), dabigatran etexilate (Pradaxa), apixaban (Eliquis), rivaroxaban (Xarelto), clopidogrel (Plavix), cilostazol (Pletal), prasugrel (Effient), and ticagrelor (Brilinta). Aspirin, other nonsteroidal anti-inflammatory drugs (NSAIDs), herbal remedies (e.g., ginkgo biloba), and dietary supplements (e.g., phentermine) were not specifically continued or discontinued for any injection type in this study.

Spinal epidural hematoma was the primary outcome. Investigators monitored for events through telephone call 24–48 hours postinjection, in-clinic appointments, or patient self-report. Magnetic resonance imaging (MRI) was performed in patients complaining of new-onset or worsening of lower extremity numbness, weakness, pain, or paresis after the intervention. Imaging was only performed where clinically appropriate. All injections were performed under fluoroscopic guidance in an operating room setting by the primary author in accordance with SIS 2013 guidelines [6]. For patients receiving multilevel injections, each injection site was considered a discrete observation.

Statistical Analysis

The number of observations needed to achieve statistical power ($1-\beta$) of 0.95 was 1,536 injections, assuming an event incidence of one in 10,000 with precision of 0.1% [9]. Outcome incidence was reported with adjusted Wald confidence intervals (CIs) within 95% [10]. Values for INR were presented as mean \pm standard deviation. Analysis was performed using JMP 12.2.0. (SAS Institute Inc., Cary, NC, USA).

Results

A total of 74 patients underwent interventional spine procedures while continuing antiplatelet/anticoagulant agents. For 197 injections (4.3% of 4,253 procedures and injections), there were no clinically evident bleeding complications on anticoagulant/antiplatelet drugs (Figure 1). Injection types where agents were continued included lumbar transforaminal epidural (N=90), posterior-approach facet joint (N=62, 4 cervical and 58 lumbar), lumbar intradiscal (N=11), sympathetic paravertebral (N=3), and sacroiliac (N=5) injections, as well as radiofrequency neurotomy (N=26, 3 cervical and 23 lumbar).

Agents continued during injection included clopidogrel (N=79), warfarin (N=87), dabigatran (N=10), cilostazol (N=12), apixaban (N=9), rivaroxaban (N=9), prasugrel (N=3), and ticagrelor (N=4) (Figure 1). The most common injection-agent combination was lumbar transforaminal injection performed while continuing clopidogrel (N=30) or warfarin (N=37). Median and interquartile range INR for patients injected while on warfarin was 2.4 ± 0.9 .

One spinal epidural hematoma occurred in an 87-year old female with spinal stenosis undergoing lumbar interlaminar epidural steroid injection. She experienced left lower extremity paresthesia and paresis, which improved

Table 1 The Modified SIS 2013—ASRA 2015 anticoagulant & antiplatelet guideline table

	High Risk		Low Risk	
		Intermediate-High Risk	Intermediate-Low Risk	
	Vertebral augmentation	C,T,S1 Transforaminal	L Transforaminal	
	Intrathecal catheter	C,T Disc Stimulation	L Disc Stimulation	C,T,L Medial
	Spinal cord stimulation	Interlaminar Epidural Inj	L Sympathetic	Branch Block or Z
		Caudal Epidural Inj	Hypogastric plexus	(Facet) Joint Inj,
Medications		Atlanto-Axial Joint B	Ganglion impar	posterior approach
			RF Neurotomy	SI Joint Inj
Aspirin, including combinations	Shared decision-making*		Continue	
Nonaspirin NSAIDs	Consider off for 5 half-lives		Continue	
COX-2 inhibitors, SSRIs	Continue		Continue	
<u>General anticoagulants</u>				
Enoxaparin (LMWH)	Off 12–24 h		Off 12–24 h	
Heparin, unfractionated	Continue if dose <5,000 units twice daily		Continue	
Warfarin	Off 4–5 days INR ≤ 1.3 on day of procedure		INR at lowest recommended therapeutic range	
<u>Phosphodiesterase inhibitors</u>				
Cilostazol, pentoxifylline	Off 2 days		Continue	
Dipyridamole	Off 2–7 days		Continue	
<u>Novel oral anticoagulants</u> (NOACs: direct thrombin and Xa inhibitors)				
Apixaban, edoxaban, Rivaroxaban	Off 3 days		Continue	
Dabigatran	Off 5 days Off 6 days in renal impairment		Continue	
<u>Glycoprotein IIb/IIIa inhibitors</u>				
Eptifibatide, tirofiban	Off 8–24 hours		Off 8–24 hours	
Abciximab	Off 3–5 days		Off 3–5 days	
<u>P2Y12 inhibitors</u>				
Ticagrelor	Off 5 days		Continue	
Clopidogrel, prasugrel	Off 7 days		Continue	
Ticlopidine	Off 14 days		Continue	
<u>Fibrinolytic agents</u>				
Fondaparinux	Off 4 days		Continue	

The Modified SIS-ASRA Antiplatelet & Anticoagulant guideline table management prior to interventional spinal procedures. Clinical judgment supersedes recommendations as each patient-procedure scenario is different. Ceasing antiplatelet/anticoagulant agents should occur in consultation with the prescribing provider. From left to right, risk of bleeding decreases based on firm evidence (far left and far right columns) and theoretical/mechanistic suggestions (middle two columns). In creating the table above, the authors favored SIS 2013 guidelines over those of ASRA 2015 with regard to continuing agents for lumbar (L₁-L₅) transforaminal epidural, posterior-approach facet joint, sympathetic, sacroiliac, and lumbar intradiscal injections. Where vertebral level is not specified, all levels are implied.

*The indication for aspirin use should be assessed, and shared decision-making regarding procedural management should be coordinated between the prescribing physician and pain interventionalist.

B = block; C = cervical; COX = cyclooxygenase; inj = injection; INR = international normalized ratio; L = lumbar; LMWH = low molecular weight heparin; NSAID = nonsteroidal antiinflammatory drug; RF = radiofrequency; SI = sacro-iliac; T = thoracic; Z = zygapophyseal.

with conservative, nonsurgical management. The incidence of spinal epidural hematoma for interlaminar injections was one in 2,026 injections (0.05%, 95% CI = 0.00–0.31) (see Table 2). Overall incidence for all procedures studied was

one in 4,047 procedures (0.02%, 95% CI = 0.00–0.15%). A total of 191 cervical and 723 lumbar transforaminal epidural injections were performed: no anticoagulant/antiplatelet agent was continued during cervical transforaminal injection.

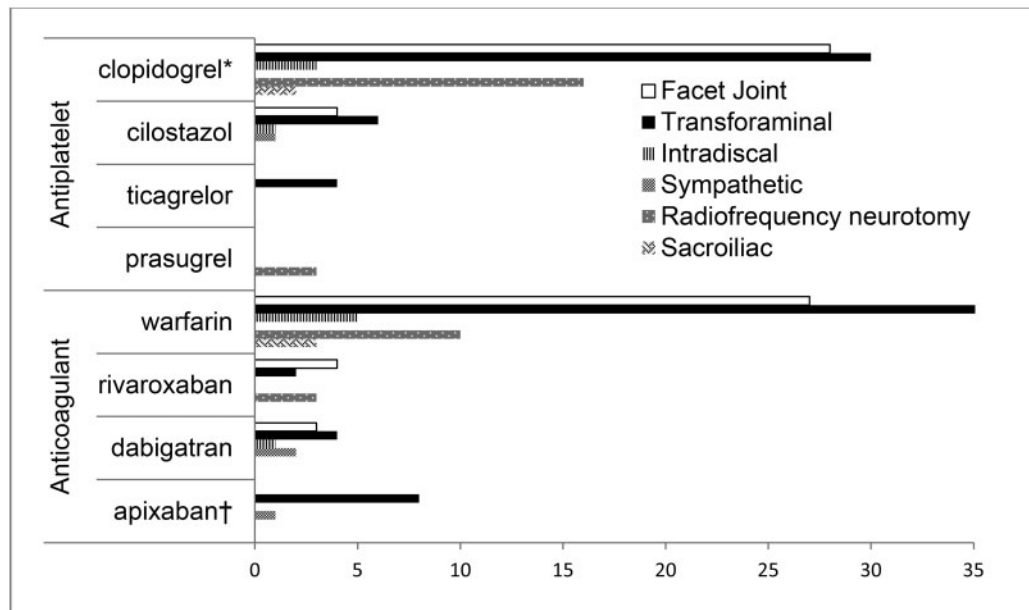


Figure 1 Anticoagulant and antiplatelet agent continuation by injection type. Seventy-four patients underwent 197 spinal injections under fluoroscopic guidance while continuing oral anticoagulant/antiplatelet medications. The horizontal axis represents number of injections. Eighteen injections were performed in patients continuing dual-agent combinations: *six lumbar transforaminal epidural, four lumbar facet joint injections, and six lumbar radiofrequency neurotomies on warfarin-clopidogrel dual therapy; †two lumbar transforaminal epidural injections on apixaban-ticagrelor dual therapy.

Table 2 Interventional spine procedures and incidence of epidural hematoma

Procedure	Epidural hematoma	Event incidence, % (range)	N C or T	N L or S	Agent continued N (%)
Interlaminar/caudal epidural inj	1 in 2,026	0.05 (0–0.3)	550	1,476	0 (0.0)
Vertebral augmentation	0 in 41	N/A	16	25	0 (0.0)
Spinal cord stimulator	0 in 2	N/A	0	2	0 (0.0)
Transforaminal epidural inj	0 in 914	0 (0–0.5)	191	723	90 (9.8)
Lumbar Intradiscal inj	0 in 391	0 (0–1.2)	0	391	11 (2.8)
Cervical facet joint inj	0 in 247	0 (0–1.9)	247	0	4 (1.6)
Lumbar facet joint inj	0 in 417	0 (0–1.1)	0	417	58 (13.9)
Sympathetic paravertebral inj	0 in 29	N/A	0	29	3 (10.3)
Cervical RF neurotomy	0 in 18	N/A	18	0	3 (16.7)
Lumbar RF neurotomy	0 in 119	N/A	0	119	23 (19.3)
Sacroiliac joint inj	0 in 49	N/A	0	49	5 (10.2)
Aggregate	1 in 4,253	0.02 (0.00–0.15)	1,022	3,231	197 (4.6)

Complication incidence was computed for procedures performed from February 1, 2015 through June 7, 2016. Denominators were determined from current procedural terminology (CPT) codes. The far right column represents the count and percentage of procedures where antiplatelet and anticoagulant drugs were continued.

C = cervical; CI = confidence interval; inj = injection; L = lumbar; N = number of injections; N/A = not available; RF = radiofrequency; S = sacral; T = thoracic.

No thromboembolic events (myocardial infarction, cerebrovascular accident, or critical limb ischemia) were observed within 24–48 hours after spinal injection for all patients in the study.

Discussion

Management of periprocedural antiplatelet and anticoagulant medications requires balancing risk of

hemorrhagic vs thromboembolic complications [5]. Interventionalists, physiatrists, primary care physicians, anesthesiologists, and cardiologists should tailor therapy for patients undergoing high-risk procedures. Communication among providers regarding the indication (e.g., primary prophylaxis of myocardial infarction or stroke, peripheral vascular disease, etc.) for aspirin use should guide management in a patient- and procedure-specific manner [8]. Patients benefit from adherence to consensus guidelines: Four of seven epidural hematomas with intrathecal catheter insertion or removal occurred in patients whose antiplatelet/anticoagulant therapy deviated from 2003 ASRA guidelines [7,11]. Notwithstanding, guidelines must adapt to reflect the most up-to-date clinical knowledge base in order to ensure patient safety.

The current study adds to the fund of safety data for interventional spine procedures. A recent study of 4,766 patients undergoing various spinal interventions reported nine thromboembolic events linked to preprocedural warfarin cessation [12]. This same endeavor by Endres et al. reported no hemorrhagic events after lumbar transforaminal, lumbar medial branch, trigger point, and sacroiliac joint injections in 4,154 patients continuing anticoagulant medications. The current study further validates the relative safety of continuing anticoagulants during these procedures.

Our findings extended similar conclusions to patients undergoing radiofrequency neurotomy: 26 injections (three cervical, 23 lumbar) were performed while continuing anticoagulation/antiplatelet medication without bleeding incidents (Table 2). For radiofrequency procedures, cautery theoretically enhances local hemostasis. Furthermore, posterolateral and posterior approaches in these procedures advance the needle tip relatively distant to the central spinal canal. On the other hand, introduction and manipulation of electrodes may increase risk of vascular damage [12]. Anticoagulant and antiplatelet medications are controversial for radiofrequency neurotomy or ablation, and ongoing investigation is advised.

The present study contains the third known report of epidural hematoma following interlaminar epidural steroid injection. Aside from one other prospective evaluation of spine procedures [13], this study includes the largest number of interlaminar epidural injections. Benyamin et al. reports a cervical hematoma developing hours after cervical interlaminar injection in a patient whose clopidogrel therapy was held for 12 days [14]. This event required urgent C₄-T₃ decompressive laminectomy. We report a lumbar epidural hematoma in a patient who was not prescribed any anticoagulant or antiplatelet drug and whose symptoms improved with nonsurgical management. Indeed, risk of bleeding from interlaminar injections surpasses that of transforaminal approaches of epidural injection [6,8,12,15,16]. Thus, interlaminar approaches should prompt discontinuation of anticoagulant or antiplatelet agents if feasible.

Within a single-center, single-provider practice, we have validated that anticoagulant and antiplatelet medications may be continued in select procedures without bleeding complications. These data capture how commonly interventionalists encounter the “continue or hold” conundrum in real-life practice. For instance, we report 90 of 729 (12.4%) lumbar transforaminal epidural injections performed while continuing anticoagulation/antiplatelet medications. On the other hand, Endres et al. reported that 1,633 of 2,389 (68%) transforaminal epidural injections were performed while maintaining anticoagulation. In both this study and the Endres et al. report, agent continuation is at the provider’s discretion. The pervasiveness of the “continue or hold” question may differ by patient population, the physicians’ procedural repertoire, the guidelines utilized for management, and other considerations.

Bleeding risk certainly differs among procedure and injection types. The paucity of prospective data limits current knowledge of these rare bleeding complications following interventional spine procedures. Current interventional spine guidelines are without recommendation grade [1,8] as they are based largely on compilations of case reports, borrowed literature from catheter-based/neuraxial anesthesia fields [7,11], and theoretical or pharmacologic postulates. Continued monitoring of patient outcomes through larger multicenter efforts will provide further insights into risk of adverse events.

Modified SIS 2013—ASRA 2015 Antiplatelet & Anticoagulant Guideline Rationale

The authors initially developed a guideline table from recommendations of SIS 2013 [6]. Later, ASRA released guidelines in 2015 that categorized bleeding risk by procedure [8]. Dissent arose between SIS 2013 and ASRA 2015 regarding antiplatelet/anticoagulant management for lumbar transforaminal epidural, lumbar sympathetic block, posterior approach facet joint (any level), radiofrequency neurotomy, and lumbar intradiscal injections; ASRA 2015 classified these procedures as “intermediate risk.” We favored the SIS 2013 guidelines with regard to the discrepancies above by categorizing these procedures as theoretically low risk (Table 1). Additionally, for sacroiliac and other extraspinal injections, SIS stated that risk is “next to zero...in patients who continue to take anticoagulants.”

ASRA proposed holding antiplatelet agents, warfarin, and novel oral anticoagulants prior to “intermediate risk” procedures. For lumbar (but not cervical, thoracic, or sacral) transforaminal epidural injection, SIS cited that there have been no reports of postinjection epidural hematoma. Since this publication, the authors identified only one reported case of bleeding after lumbar transforaminal epidural injection, although not within the epidural space: an L₄-L₅ perineural hematoma followed a right L₄ transforaminal epidural injection in a 72-year-old who was not

taking anticoagulant or antiplatelet drugs, had no underlying coagulopathy, and experienced symptom resolution without decompressive surgery [17]. Cervical, thoracic, and sacral transforaminal epidural approaches carry greater risk of spinal complication. In the event of bleeding, there are theoretically greater risks of neural injury due to various anatomic considerations (i.e., spinal cord and intraspinal needle placement). Thus, providers should consider holding antiplatelet and anticoagulants for these interventions [6].

Dipyridamole, a phosphodiesterase-3 and -5 inhibitor, is often combined with aspirin for synergistic inhibition of coagulation. ASRA recommends ceasing dipyridamole without aspirin for two days prior to high-risk procedures only [6], while the Physiatric Association of Spine, Sports and Occupational Rehabilitation (PASSOR) guidelines from the American Academy of Physical Medicine and Rehabilitation state dipyridamole (with or without aspirin) should be ceased for at least seven days [18].

Since the publication of the ASRA 2015 guidelines, the oral factor X_a inhibitor edoxaban (Savaysa) was approved by the US Food and Drug Administration. Holding this medication for five half-lives ($t_{1/2}$: 10–14 hours) as is proposed for other oral X_a inhibitors during high- and intermediate-risk procedures seems advisable [8,19].

Neural complications from spinal intervention are mostly ischemic, not hemorrhagic, in nature [3,20–26]. In patients at higher risk for vascular injury (e.g., history of previous spinal surgery at the level of injection, paraspinal adhesions, etc.), holding hemostatically active agents even for low-risk procedures may be reasonable [27]. In this study, medications were not held for patients who previously had spinal surgery. Notwithstanding, most of the procedures studied in the current endeavor are categorized as intermediate risk according to ASRA 2015. Notable exceptions included vertebral augmentation (high risk) and sacroiliac injection (low risk).

Limitations

The study findings must be interpreted in the context of its limitations. Incidence of epidural hematoma could be calculated within goal precision (0.1%) for interlaminar epidural injections alone. Of note, this is the only epidural hematoma to result from spinal injection in the primary author's 21 years of practice. Thus, the current study may overestimate epidural hematoma incidence after interlaminar injection.

CPT coding data precluded distinguishing between sacral and lumbar transforaminal epidural injections; no sacral transforaminal epidural injection was performed while continuing antiplatelet/anticoagulant agents. Similarly, interlaminar and caudal epidural injections could not be distinguished based on CPT coding (Table 2). Of note, no patient continued antiplatelet/anticoagulant medication for interlaminar or caudal epidural injection. Four of 82 (4.6%) injections during warfarin therapy

had missing INR values and were not imputed in the analysis.

Continuation or discontinuation of aspirin, other NSAIDs, and selective serotonin reuptake inhibitor (SSRI) was not monitored. ASRA 2015 and ASIPP guidelines recommend continuing NSAIDs during intermediate- to low-risk procedures. With regard to aspirin, shared physician decision-making between the prescribing provider and interventionalist should occur on a patient- and procedure-specific basis. In our experience, patients often continue or discontinue these medications without explicit instruction. Medical indication for antiplatelet/anticoagulant agents was not included in the analysis.

This prospective descriptive study utilized a convenience sample from one provider's practice in the southeastern United States. As epidural hematomas are rare complications after common spinal interventions, continued multicenter prospective efforts are essential to determine bleeding risk per agent and per procedure.

Conclusions

Radiographically guided lumbar (L₁-L₅) transforaminal epidural and posterior-approach facet joint injections appear to be lower-risk procedures for bleeding. Continuation of clopidogrel or warfarin for lumbar transforaminal epidural and posterior-approach facet joint injections may be reasonable. Interlaminar injections carry greater bleeding risk and merit consideration of holding anticoagulant/antiplatelet agents. The Modified SIS 2013—ASRA 2015 Antiplatelet & Anticoagulant guideline table may serve as a useful reference tool for spine interventionalists pending large multicenter efforts validating its implementation.

Acknowledgments

There were no assisting individuals in addition to the authors of this manuscript.

References

- 1 Manchikanti L, Abdi S, Atluri S, et al. An update of comprehensive evidence-based guidelines for interventional techniques in chronic spinal pain. Part II: Guidance and recommendations. *Pain Physician* 2013;16:S49–283.
- 2 Benny B, Azari P. The efficacy of lumbosacral transforaminal epidural steroid injections: A comprehensive literature review. *J Back Musculoskelet Rehabil* 2011;24:67–76.
- 3 Goodman B, Posecion L, Mallempati S, Bayazitoglu M. Complications and pitfalls of lumbar interlaminar and transforaminal epidural injections. *Curr Rev Musculoskelet Med* 2008;3–4:212–22.

- 4 Douketis J, Spyropoulos A, Kaatz S, et al. Perioperative bridging anticoagulation in patients with atrial fibrillation. *N Engl J Med* 2015;373:823–33.
- 5 Furman M, Tekmester G, Davidoff S, Plastaras S, Popescu A. Should antiplatelet medications be held before cervical epidural injections? *PM R* 2014;6:442–50.
- 6 Bogduk N. Practice Guidelines for Spinal Diagnostic and Treatment Procedures, 2nd edition; 2013. Location: San Francisco, CA: Publisher: International Spine Intervention Society.
- 7 Bateman B, Mhyre J, Ehrenfeld J, et al. The risk and outcomes of epidural hematomas after perioperative and obstetric epidural catheterization: A report from the Multicenter Perioperative Outcomes Group Research Consortium. *Anesth Analg* 2013;116:1380–5.
- 8 Narouze S, Benzon H, Provenzano D, et al. Interventional spine and pain procedures in patients on antiplatelet and anticoagulant medications: Guidelines from the American Society of Regional Anesthesia and Pain Medicine, the European Society of Regional Anaesthesia and Pain Therapy, the American Academy of Pain Medicine, the International Neuromodulation Society, the North American Neuromodulation Society, and the World Institute of Pain. *Reg Anesth Pain Med* 2015;40:182–212.
- 9 Eng J. Sample size estimation: How many individuals should be studied? *Radiology* 2003;227:309–13.
- 10 Agresti A, Coull B. Approximate is better than “exact” for interval estimation of binomial proportions. *Am Statistician* 1998;52:119–26.
- 11 Horlocker T, Wedel D, Benzon H, et al. Regional anesthesia in the anticoagulated patient: Defining the risks (the second ASRA Consensus Conference on Neuraxial Anesthesia and Anticoagulation). *Reg Anesth Pain Med* 2003;28:172–97.
- 12 Endres S, Shufelt A, Boduk N. The risks of continuing or discontinuing anticoagulants for patients undergoing common interventional pain procedures. *Pain Med* 2016;18:403–9.
- 13 Manchikanti L, Malla Y, Wargo B, et al. A prospective evaluation of complications of 10,000 fluoroscopically directed epidural injections. *Pain Physician* 2012;15:131–40.
- 14 Benyamin R, Vallejo R, Wang V, et al. Acute epidural hematoma formation in cervical spine after interlaminar epidural steroid injection despite discontinuation of clopidogrel. *Reg Anesth Pain Med* 2016;41:398–401.
- 15 Chien G, McCormick Z, Araujo M, Candido K. The potential contributing effect of ketorolac and fluoxetine to a spinal epidural hematoma following a cervical interlaminar epidural steroid injection: A case report and narrative review. *Pain Physician* 2014;17:E385–95.
- 16 Page J, Moisi M, Oskouian R. Lumbar epidural hematoma following interlaminar fluoroscopically guided epidural steroid injection. *Reg Anesth Pain Med* 2016;41:402–4.
- 17 Desai M, Dua S. Perineural hematoma following lumbar transforaminal steroid injection causing acute-on-chronic lumbar radiculopathy: A case report. *Pain Pract* 2014;14:271–7.
- 18 Casazza B, Chou L, Davis S, et al. Educational guidelines for interventional spinal procedures. *Amer Acad Physical Med Rehab* 2008;4:3–48.
- 19 Lip G, Agnelli G. Edoxaban: A focused review of its clinical pharmacology. *Eur Heart J* 2014;35:1844–55.
- 20 Thefenne L, Dubecq C, Zing E, et al. A rare case of paraplegia complicating a lumbar epidural infiltration. *Ann Phys Rehabil Med* 2010;53:575–83.
- 21 Huntoon M, Martin D. Paralysis after transforaminal epidural injection and previous spinal surgery. *Reg Anesth Pain Med* 2004;29:494–5.
- 22 Tackla R, Keller J, Ernst R, Farley C, Bohinski R. Conus medullaris syndrome after epidural steroid injection: Case report. *Int J Spine Surg* 2012;6:29–33.
- 23 Lyders E, Morris P. A case of spinal cord infarction following lumbar transforaminal epidural steroid injection: MR imaging and angiographic findings. *AJNR Am J Neuroradiol* 2009;30:1691–3.
- 24 Glaser S, Falco F. Paraplegia following a thoracolumbar transforaminal epidural steroid injection. *Pain Physician* 2005;8:309–14.
- 25 Houten J, Errico T. Paraplegia after lumbosacral nerve root block: Report of three cases. *Spine J* 2002;2:70–5.
- 26 Kennedy D, Dreyfuss P, Aprill C, Bogduk N. Paraplegia following image-guided transforaminal lumbar spine epidural steroid injection: Two case reports. *Pain Med* 2009;10:1389–94.
- 27 Horlocker T. Regional anaesthesia in the patient receiving antithrombotic and antiplatelet therapy. *Brit J Anesth* 2011;107:i96–106.