



Eosinophilic Esophagitis



Clinical Presentation



Young Children

Food refusal
Texture aversion
Vomiting with meals



Older Children

Abdominal pain
Vomiting



Young Adults

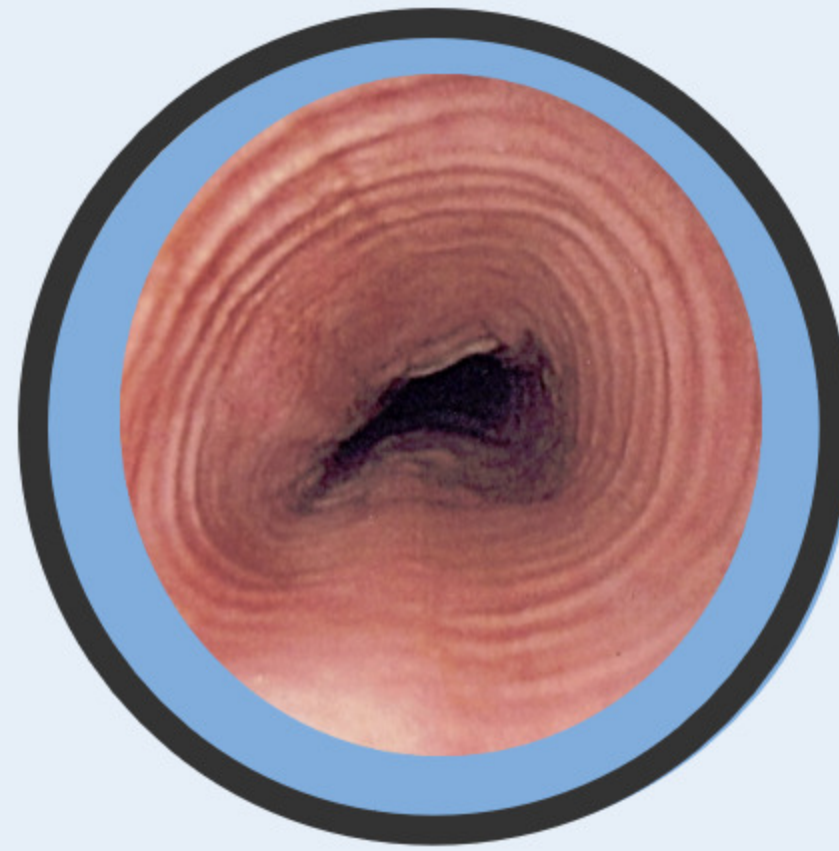
Dysphagia
Food impaction



Diagnosis

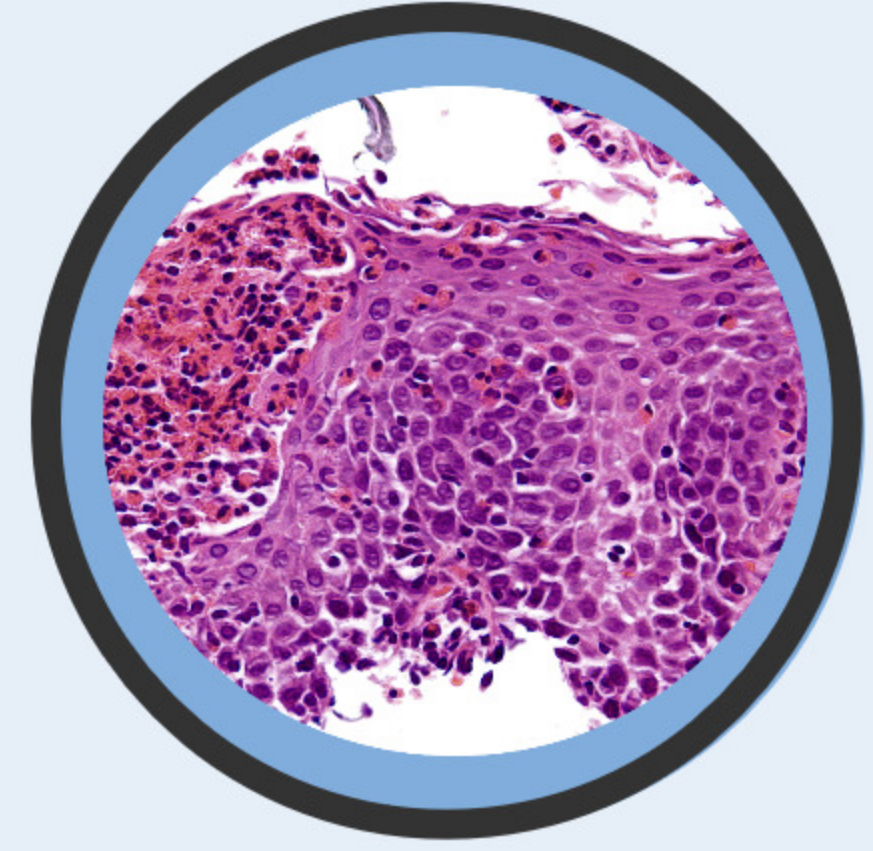


Clinical Symptoms



Endoscopy

Linear furrows
Esophageal rings
Possible strictures



Biopsy

15 eosinophils per high power field in proximal and distal esophagus
Absent in stomach



Management



Proton Pump Inhibitor

Twice Daily
For diagnosis & management of PPI responsive EoE



Topical Steroids

Swallowed, not inhaled
I.e. fluticasone



Dietary Modifications

Milk, wheat, soy, eggs, nuts, fish



Dilation

If strictures are present