

# **Somatic Dysfunction: An Osteopathic Conundrum**

Gary Fryer, B.Sc.(Osteopathy), Ph.D.<sup>1, 2</sup>

<sup>1</sup> Centre for Chronic Disease Prevention and Management, College of Health and Biomedicine, Victoria University, Melbourne, Australia

<sup>2</sup> A.T. Still Research Institute, A.T. Still University, Kirksville, Missouri, USA

*Corresponding Author:*

Associate Professor Gary Fryer, College of Health and Biomedicine, Victoria University, PO Box 14428 MCMC, Melbourne, 8001, Australia. Phone: +61 3 99191065

Email: [gary.fryer@vu.edu.au](mailto:gary.fryer@vu.edu.au)

## ABSTRACT

Somatic dysfunction is considered a central concept for the theory and practice of osteopathy, but its relevance to the modern profession is questionable due to its unclear pathophysiology and poor reliability of detection. This article will explore the factors that may produce clinical signs attributed to somatic dysfunction and discuss the plausibility of the concept. A conceptual model is presented for the clinical diagnostic cues attributed to intervertebral somatic dysfunction, where signs of dysfunction arise from tissue and neurological factors related by a cycle of tissue injury and nociceptive-driven functional changes. Finally, the relevance of the concept of somatic dysfunction to the modern osteopathic profession is discussed and recommendations for the osteopathic profession are made.

Keywords: osteopathic medicine, diagnosis, palpation, somatic dysfunction

## INTRODUCTION

Long before the inception of osteopathy, practitioners of manual therapy tried to understand and explain the causes and relevance of clinical palpatory findings which appear to be associated with patient complaints and resolve following manual manipulation. Over the years, many theories, both simple and complex, were postulated to explain the palpatory findings and provide a rationale for manual treatment.

Somatic dysfunction, and its predecessor term ‘osteopathic lesion’, has been considered a central concept of the theory and practice of osteopathy for over a hundred years.<sup>1,2</sup> For many practitioners, the term represents a single clinical entity, diagnosed exclusively by osteopaths using palpation, that impacts pain, function, and general health, and is appropriately treated using manipulation. For others, somatic dysfunction represents an anachronistic, obsolete concept from the early 20th century that reinforces the belief in an esoteric, structural cause of pain. This article will explore the factors that may produce clinical signs attributed to somatic dysfunction and discuss the plausibility and relevance of the concept of somatic dysfunction to the modern profession. The author contends that a broad conceptual model for these palpatory cues may assist clinical reasoning during physical examination, but that the term ‘somatic dysfunction’ no longer has clinical utility when formulating a diagnosis or describing clinical findings to other practitioners.

Somatic dysfunction has been defined as ‘impaired or altered function of related components of the somatic (body framework) system: skeletal, arthroidal, and myofascial structures, and related vascular, lymphatic, and neural elements.’<sup>3</sup> It is proposed to be a reversible, functional disturbance that predisposes the body to disease,<sup>4</sup> where manipulation is the specific and effective treatment.<sup>5</sup> The term can be used broadly to denote dysfunction of a group of tissues or a region, or used more specifically for dysfunction of a single articulation. Somatic dysfunction is not synonymous with spinal pain, and palpable signs of

dysfunction may be detected in symptomatic and asymptomatic individuals.<sup>6</sup> It has been proposed that the presence of somatic dysfunction in asymptomatic individuals creates biomechanical and neurological consequences which predispose the individual to pain and other health complaints.<sup>4,7</sup> This article will focus on the concept of somatic dysfunction of the articulations of the spinal segment, alternatively termed intervertebral somatic dysfunction, intervertebral dysfunction, intervertebral lesion, or segmental dysfunction.<sup>8-10</sup>

The author has previously explored the concept of somatic dysfunction in relation to modern evidence and suggested a model to explain the probable sources of the palpable signs of dysfunction.<sup>8,9,11</sup> In a 1999 article,<sup>8</sup> the author argued that the concept of somatic dysfunction was largely based on outdated research and that advances in the fields of motor control and pain science necessitated changes to the concept. In 2003, the author suggested a model that included patho-anatomical factors associated with strain and degeneration and nociceptive-driven functional consequences.<sup>9</sup> This model was not intended to describe somatic dysfunction per se but to offer a variety of plausible causes of the clinical signs attributed to somatic dysfunction. Because of advances in relevant evidence, this topic now requires further consideration and discussion.

Somatic dysfunction is claimed to be detected by palpation using four cardinal clinical signs: tenderness, asymmetry, range of motion abnormality, and tissue texture changes.<sup>1,5,12,13</sup> The mnemonic TART or ARTT is commonly used as a memory aid for these clinical signs. Some authors do not include tenderness as a clinical sign<sup>1</sup> or substitute 'sensitivity' for tenderness.<sup>5</sup> At least two of these signs must be present for a diagnosis of somatic dysfunction.<sup>13</sup> Most authors consider motion restriction an important feature of somatic dysfunction<sup>5,13,14</sup> although some authors describe motion abnormality as being either reduced or increased.<sup>1,12</sup> The reliability for the detection of these clinical signs will be discussed later in this article.

Somatic dysfunction is often described as a reversible functional disturbance<sup>4</sup> and is not considered to still be somatic dysfunction when pathology is present.<sup>15</sup> To consider all likely causes of the diagnostic cues of somatic dysfunction, the author proposes that tissue strain and degenerative joint change, such as that affecting the zygapophysial joints or intervertebral discs, must be taken into account in addition to the purely functional changes. Although strain and degenerative pathologies can be considered as comorbidities to the functional disturbances,<sup>11</sup> the inability to differentiate the causes of palpatory cues using palpation alone is reason to include both pathological and functional aspects in any model of the palpatory cues of dysfunction. Other pathologies, such as inflammatory arthritides, may also potentially produce palpable change, but these conditions may be differentiated from functional and degenerative causes through the clinical history and other clinical tests.

The proposed causes of clinical signs attributed to somatic dysfunction are largely speculative and lack high-quality supporting evidence, but the author contends that it is possible to present plausible causes for the commonly cited clinical signs based on the available evidence.

#### TISSUE FACTORS CONTRIBUTING TO THE CLINICAL SIGNS OF SOMATIC DYSFUNCTION

Many tissue factors, linked by a natural history of injury and degenerative change, are likely to contribute to the palpable cues of somatic dysfunction. Tissue factors that may contribute to these palpable cues include injury and inflammation of the zygapophysial joint; entrapment or extrapment of synovial folds within the zygapophysial joint; connective tissue remodelling within and around the zygapophysial joint; and derangement or degeneration of the intervertebral discs.<sup>9</sup> Other pathologies not discussed in this article may also create palpable signs, but the patient's history will provide information about the likelihood of local

and systemic pathology, such as inflammatory arthritides, which can be confirmed with additional medical tests.

#### Injury to the zygapophysial joint

Sprain of the zygapophysial joint has been postulated as a cause of spinal pain and intervertebral dysfunction.<sup>9, 16</sup> Studies using diagnostic anaesthetising blocks have confirmed that the zygapophysial joint is a common source of spinal pain and can produce both local and referred pain.<sup>16, 17</sup> Although the cause of pain remains elusive, zygapophysial joint capsule tears and avulsion fractures have been identified following injury.<sup>16</sup>

Trauma may therefore cause zygapophysial joint capsule sprain, inflammation, and joint effusion, as well as injury to other tissues around the intervertebral segment. As a result, it is plausible that sprain and effusion may cause or contribute to all of the diagnostic signs of segmental somatic dysfunction: pain and deep paraspinal tenderness from ligament and capsule inflammation, restricted joint motion with altered joint end-feel from joint effusion and tissue congestion, and tissue texture changes such as hardness or ‘bogginess’ from inflammation and congestion of the periarticular muscles and tissues.

Although zygapophysial joint sprain seems to be a plausible cause of acute spinal pain, there is a lack of supporting clinical evidence. Nazarian et al.<sup>18</sup> investigated cervical and lumbar zygapophysial joint inflammation in symptomatic patients using diagnostic ultrasound but were unable to demonstrate abnormal echogenicity in or adjacent to the joints. Fryer and Adams<sup>19</sup> examined five volunteers with acute unilateral ‘crick in the neck’ pain within 24 hours of pain onset; the authors postulated that this population would be likely to have inflammatory signs. Volunteers were examined to determine the side and level of neck pain, and the examination was followed by magnetic resonance imaging of the neck. No evidence of cervical joint inflammation or joint effusion was detected, but the study could not discount the possibility that occult inflammation was present and more sensitive imaging

methods were necessary for detection.<sup>19</sup> Therefore, if inflammation does occur in the zygapophysial joints in volunteers with acute benign neck pain following trivial trauma, it must be subtle.

#### Entrapment or extrapment of synovial folds

Entrapment or extrapment of synovial folds has been proposed as a mechanism for acute spinal joint pain with locking.<sup>5, 16, 20</sup> Meniscoid-like synovial folds occur within the zygapophysial joints of the lumbar and cervical spine and act as 'passive space-fillers' that fill peripheral non-congruent parts of the joint in its neutral position but displace when the joint moves.<sup>16, 20</sup>

Some authors have speculated that these synovial folds become entrapped (swollen and inflamed from minor trauma that prevents the gliding of the opposing joint surfaces) or extrapped (buckled and caught on the joint margin during full flexion that prevents the superior joint surface from gliding downwards and backwards).<sup>5, 16, 20</sup> The clinical significance of these synovial folds is largely unknown, but they are likely injured and become a source of pain in traumatic neck conditions such as whiplash.<sup>20</sup> The entrapment and extrapment hypotheses seem plausible for somatic dysfunction where the spinal joint is acutely painful and 'locked' in flexion, but these explanations are speculative because of lack of direct evidence.<sup>16, 20</sup>

#### Articular connective tissue changes

Intra-articular adhesions, joint fibrosis, and ligament laxity have all been suggested as consequences of injury and causes of disturbed joint mobility.<sup>8, 9, 21-23</sup> Adhesions within the zygapophysial joint have been suggested as a cause of restricted segmental mobility.<sup>21, 22</sup> Although adhesions have been observed in rats following zygapophysial joint immobilization by surgical fixation,<sup>22</sup> evidence is lacking in humans. Intra-articular adhesions would not account for acute or transient hypomobility because of the time required for adhesion

formation, but adhesions should be a theoretical consideration where chronic segmental hypomobility follows a period of immobilization.

Alternatively, ongoing strain and injury to the zygapophysial capsule and capsular ligaments may produce remodelling and lengthening of these connective tissues. Ongoing strain may cause viscoelastic creep, injury, and remodelling of the joint ligaments, leading to long-term ligament laxity and joint hypermobility.<sup>23, 24</sup> Injured ligaments heal with scar tissue, which weakens the biomechanical properties of the tissue and does not completely recover over time.<sup>25, 26</sup> Although somatic dysfunction is typically proposed to involve segmental hypomobility,<sup>5, 14, 27</sup> some authors state that the clinical sign of 'altered' motion in somatic dysfunction also includes hypermobility.<sup>1, 12</sup> Where segmental hypermobility has developed, the segment may become more susceptible to further injury and sprain, which would reinforce other clinical signs of dysfunction, such as tenderness and tissue texture change.

In either case, connective tissue remodelling of the capsule and ligaments may be responsible for long-term mobility changes. There is greater evidence of ligament laxity and hypermobility than for hypomobility associated with spinal pain, particularly following trauma such as whiplash,<sup>23</sup> and, given the lack of direct evidence for intra-articular adhesions and capsule fibrotic changes in humans, these potential causes of hypomobility are more speculative. However, intra-articular adhesions may be more plausible causes of joint hypomobility when injury is followed by a prolonged period of immobilization.<sup>22</sup>

#### Intervertebral disc degeneration

Intervertebral discs are a source of chronic low back pain but usually cannot be diagnosed from either the history or physical examination.<sup>16, 28</sup> Some authors have attributed signs of segmental somatic dysfunction, such as pain from manual pressure and end-range motion testing, to internal disruption of the disc and migration of the nucleus.<sup>21, 29, 30</sup>

Although disc degeneration can be unrelated to spinal pain or symptoms,<sup>31, 32</sup> degeneration reduces motion of the segment in all directions which potentially may be detected by motion palpation and accessory motion testing.<sup>33, 34</sup> Injury to the disc can produce reflex multifidus contraction<sup>35</sup> and potentially produce palpable paraspinal tissue change, but the evidence for abnormal electromyographic activity associated with palpatory findings is lacking.<sup>36-38</sup> Therefore, intervertebral disc injury, disruption and degeneration have the potential to produce many of the cardinal signs of somatic dysfunction, particularly reduced segmental motion. Other specific inflammatory arthritides and spinal pathologies may also cause pain and palpable cues, but are not considered here because they typically will be identified by clinical history and diagnostic imaging and are not commonly the result of minor injury or degenerative change.

#### NOCICEPTIVE-DRIVEN FUNCTIONAL CHANGES CONTRIBUTING TO THE CLINICAL SIGNS OF SOMATIC DYSFUNCTION

Neurological models for somatic dysfunction have gained the most acceptance and longevity in the osteopathic profession. Korr developed the ‘facilitated segment’ model<sup>39, 40</sup> based on pioneering research conducted in the 1940s and 1950s. His research suggested myofascial insults could produce exaggerated segmental motor and sympathetic responses.<sup>41-43</sup> However, this research had major shortcomings and did not validate the somatic dysfunction concept.<sup>44, 45</sup> In Korr’s model, aberrant afferent input into the spinal cord following poorly executed movement or trauma was proposed to ‘facilitate’ and lower the threshold of spinal interneurons, producing exaggerated sensory, motor, and sympathetic outflow from the involved segment. In 1990, Van Buskirk offered a modification of the Korr model that emphasised the importance of the nociceptor in producing motor and sensory responses.<sup>46</sup> Van Buskirk also highlighted the possible role of the nociceptor axon reflex in

producing tissue changes.<sup>46</sup> In both models, segmental motion disturbances were attributed to muscle contraction or contracture, and tissue changes were largely attributed to muscle contraction. However, there is little evidence that abnormal muscle contraction is associated with somatic dysfunction<sup>36, 37</sup> and abnormal electromyography activity has not been found in the deep paraspinal spinal muscles that appear abnormal to palpation at rest in recent studies.<sup>38, 47</sup>

As our understanding of pain science has expanded in recent decades, Korr's concept of the facilitated segment model has largely been superseded by the modern concept of central sensitisation. The two concepts share several similar features, including initiation by a bombardment of afferent activity, sensitisation of dorsal horn neurons, and facilitation of nociceptive pathways. However, the facilitated segment model emphasised sympathetic motor effects and segmental changes and provided a rationale for manipulative treatment to influence both musculoskeletal and visceral complaints,<sup>7</sup> whereas central sensitisation was developed to explain the pain experience and involves all forms of pain sensitisation that arise within the central nervous system (CNS), including the higher centres.<sup>48</sup> Central sensitisation occurs when nociceptor inputs trigger a prolonged increase in the excitability and synaptic efficacy of neurons in central nociceptive pathways.<sup>49</sup> Functional and anatomical reorganisation in the dorsal horn and higher centres of the CNS produce prolonged nociceptive pathway activation. The underlying neuroplastic processes have been well described elsewhere.<sup>49, 50</sup> Dorsal horn neuronal hyperexcitability has been demonstrated following painful facet joint injury,<sup>51</sup> although nociceptive input and subsequent sensitisation may originate from input by any innervated tissue.

The clinical features of central sensitisation are hyperalgesia, where normally painful stimuli produce exaggerated pain; allodynia, where normally non-painful stimuli such as light touch or motion produce pain; and a general increase in responsiveness to a variety of other

stimuli.<sup>52</sup> The exaggerated pain response to stimuli may outlast the original peripheral tissue injury, resulting in the pain transitioning to a CNS origin. Therefore, central sensitisation, with its aspects of hyperalgesia and allodynia, explains the clinical finding of tenderness when assessing for somatic dysfunction, even when a tissue source of injury may no longer be present, although tenderness may be widespread if sensitisation is a key process. The clinical implications of centrally generated pain to osteopaths are profound and will be discussed later.

Activated nociceptors may also contribute to tissue texture changes attributed to somatic dysfunction. Neurogenic inflammation regularly accompanies excitation of primary afferent nociceptors. Activated nociceptors may act in a motor fashion where antidromic action potentials from the spinal cord to the periphery cause secretion of potent pro-inflammatory neuropeptides from these sensory fibres to promote tissue inflammation.<sup>53, 54</sup> These 'dorsal root reflexes' have been found to occur in joint afferents following experimental joint arthritis<sup>55, 56</sup> and are likely to substantially contribute to inflammation in peripheral tissues.<sup>54</sup> Neurogenic inflammation has also been suggested as a possible mechanism for the inflammation and signs associated with somatic dysfunction.<sup>9, 57</sup> Although dorsal root reflexes and neurogenic inflammation are triggered by local factors in the peripheral tissues, neurogenic inflammation may also be generated from descending central pathways. Stimulation of the periaqueductal grey matter in the midbrain has been shown to produce dorsal root reflexes in a frequency-dependent manner.<sup>58</sup> Therefore, neurogenic inflammation may be responsible for causing or contributing to tissue texture changes and the tissue inflammation may or may not be related to existing peripheral tissue injury.

From a clinical perspective, pain adversely affects motor control, muscle activation and size, sensorimotor integration, and proprioception. Atrophy of deep paraspinal muscles

at the level of the painful segment has been reported in low back pain and may occur rapidly.<sup>59-62</sup> Atrophy of deep muscles may potentially be another source of abnormal palpatory findings, although atrophy has not been demonstrated in healthy participants with palpable cues.<sup>63</sup>

These nociceptive-driven functional changes may explain some of the palpable findings attributed to somatic dysfunction, specifically, central neuroplasticity and sensitisation contributing to pain and tenderness and neurogenic inflammation contributing to tissue texture changes. Although some authors<sup>4, 46</sup> have speculated that such changes may also be initiated by noxious input from viscera, the effects would likely be diffuse over several segments rather than localised to a single ‘segmental dysfunction’ because of the convergence of visceral afferents in the dorsal horn.<sup>57</sup>

#### PLAUSIBLE CAUSES FOR THE CLINICAL SIGNS OF SOMATIC DYSFUNCTION

A multitude of neurological and tissue factors may cause or contribute to the palpable cues attributed to somatic dysfunction. Nociceptive-driven functional changes may produce alterations in tissue texture and pain sensitivity, two of the cardinal features attributed to somatic dysfunction by osteopaths. Additionally, it seems likely that a number of comorbid processes involving tissue injury and degeneration will also contribute to tissue texture and range of motion changes and to activation of nociceptive pathways.

Somatic dysfunction is commonly described as being acute or chronic,<sup>5, 13</sup> and these stages likely relate to acute tissue inflammation or long-term degenerative change, with both potentially accompanied by neurological and functional changes. In the acute stage of dysfunction, tenderness is most easily explained by nociceptor activation and peripheral sensitisation following tissue injury. In the longer term, nociceptive-driven neuroplastic changes in the dorsal horn and higher CNS potentiate pain and tenderness.

Clinical signs of asymmetry, such as apparent asymmetry of paraspinal fullness, may be caused by tissue or motor changes affecting one side of the spine more than the other. Osteopathic texts and associated biomechanical models have posited that asymmetry of bony landmarks, such as transverse or spinous processes of vertebra, are clinical signs of dysfunction.<sup>1,5,13</sup> It has been proposed that a spinal segment may adopt a 'pathological' neutral resting position when there is major motion loss in one direction<sup>1</sup> or that restricted facet glide in flexion or extension may position the joint in a rotated or laterally flexed position.<sup>64</sup> However, these asymmetries and their proposed causes are entirely speculative, and natural asymmetry of bony landmarks is likely to be common and a confounder for this diagnostic sign.

Segmental motion changes in the acute stage of dysfunction may be caused by inflammatory changes and tissue fluid congestion following injury to segmental soft tissues, such as muscles, ligaments, and the joint capsule, and may be contributed by neurogenic inflammation. Despite the lack of evidence of deep inflammation in benign acute spinal pain, periarticular tissue congestion and synovial effusion could potentially occur and produce tissue resistance to full movement. Synovial fold extrapment may be responsible in rarer cases of 'locked' low back in flexion, but this mechanism is more speculative. Degenerative changes of the disc and zygapophysial joint, remodelling, and fibrosis of the joint capsule and surrounding connective tissues have the potential to cause long-term changes to the motion of the segment, either decreased or increased mobility. Further, muscle activity may contribute to motion changes. Reflex muscle guarding seems unlikely unless substantial injury to deep spinal structures has occurred, but voluntary and non-voluntary guarding behaviour due to hypervigilance and fear of pain may potentially cause motion restriction, although these changes will likely be regional rather than segmental.

Tissue texture abnormalities are most likely caused by inflammation associated with acute injury of the spine and surrounding tissues, neurogenic inflammation associated with activated nociceptors and nociceptive pathways, and guarding behaviour from muscles unable to fully relax. Additionally, deep muscle atrophy associated with spinal pain may be a source of texture change.

### A MODEL FOR THE CLINICAL SIGNS OF SOMATIC DYSFUNCTION

In the following Figure, a model is presented for the clinical signs attributed to somatic dysfunction based on previous models by the author.<sup>8,9</sup> This model does not present somatic dysfunction as a single clinical entity but as the production of clinical signs from nociceptive-driven functional changes and comorbid patho-anatomical tissue factors associated with strain and degeneration. Different factors may predominate in different individuals. This is a model for the palpatory clinical signs attributed to somatic dysfunction and not for spinal pain, and these palpable signs may exist with or without the presence of symptoms.

Dysfunction is likely initiated by tissue injury, either macro or repetitive micro-trauma. Injury of the joint capsule, periarticular soft tissues, or annulus of the disc will produce inflammation and activate nociceptors. Injury and activation of nociceptors may or may not involve conscious awareness of pain because pain is an output of the brain and modified by many factors.<sup>49,57</sup> Activation of nociceptors and nociceptive pathways may produce dorsal root reflexes to promote neurogenic tissue inflammation. This nociceptive drive may alter the motor activity of related musculatures,<sup>65-67</sup> most likely inhibiting the activity of deep segmental musculature while increasing the activation of superficial, multi-segmental musculature.<sup>36,37</sup> If pain is present, voluntary and involuntary guarding behaviour may further increase the motor output.

The nociceptive drive may also produce sympathetic arousal and, in the long-term, have an adverse impact on visceral and immune function.<sup>7, 46</sup> Traditional models of somatic dysfunction propose that 'bottom up' segmental neural reflexes produce somato-visceral changes,<sup>7, 39, 40</sup> but it is more likely that the pain experience influences the higher centres to produce generalised stress responses and autonomic arousal which cause long-term health consequences.<sup>44, 68</sup> Acute pain increases sympathetic activity and blood pressure, and, although the effects of chronic pain are more complex, chronic pain is also associated with sympathetic drive and hypertension.<sup>69</sup>

In the presence of pain, proprioception and motor control become impaired,<sup>65-67, 70-76</sup> potentially leaving the segment and region more vulnerable to further injury. Back pain appears to produce a change in motor strategy to protect and unload the injured structure, inhibiting the activation of deep spinal muscles and increasing activation of superficial lumbar musculature.<sup>36, 37, 77</sup> These changes may affect the fine motor control of the region. Individuals with chronic neck pain have been found to have jerky and irregular cervical motion<sup>70</sup> and poorer position acuity than healthy controls.<sup>70-73</sup> Neck pain patients also demonstrate greater postural sway,<sup>74</sup> a characteristic shared by patients with low back pain.<sup>75, 76</sup> Evidence suggests that pain affects the motor brain, reducing the map volume of muscles in the primary motor cortex and 'smudging' the muscle representation of different muscles in the cortex.<sup>65-67</sup> Thus, activated nociceptive pathways and the experience of pain are likely to cause poorer position acuity, motor control and stability of the painful segment or body region and to predispose to further injury.

Over time and with repeated strain and injury, degenerative changes may occur to the disc and zygapophysial joints, and even though the role of genetics may be greater than loading and lifestyle in degenerative disc disease,<sup>78, 79</sup> the factor most strongly correlated with

degeneration is age.<sup>80</sup> Degenerative change to the spinal joint complex will likely produce long-term segmental motion change, either hypermobility or hypomobility.

Although osteopathic practitioners will not be able to distinguish the underlying causes of the clinical signs they palpate, this conceptual model (Figure) may be helpful in guiding the clinical reasoning of the practitioner when considering the likely underlying processes associated with palpable signs of dysfunction. Osteopaths should also be aware that not all of these factors may be amenable to manual treatment.

### SOMATIC DYSFUNCTION: RELEVANCE TO THE MODERN PROFESSION

Although the concept of somatic dysfunction is embraced by many osteopaths as being central to the practice of osteopathy,<sup>4</sup> others consider it an anachronistic concept that threatens to bring ridicule on the profession, similarly to the discredited chiropractic subluxation.<sup>81</sup> Despite somatic dysfunction being listed as an International Classifiable Disease (ICD) with the World Health Organisation (under 'M99 Biomechanical lesions, not elsewhere classified'),<sup>82</sup> the term somatic dysfunction is vague and has no defined pathophysiology. The ICD classification most likely serves the interests of United States osteopathic physicians who use the item numbers for billing and reimbursement purposes, but the classification has little relevance to osteopaths outside the United States or to members of other professions.

Further, this author suggests that the use of the term 'somatic dysfunction' has little clinical meaningfulness for diagnostic purposes, given its lack of specificity and the likelihood that different processes produce these palpatory cues. Because the term is vague and lacks a clear pathophysiology, there is little value in communicating the presence of somatic dysfunction in patients to other osteopaths when more precise descriptors, such as restricted motion or tenderness, can be used. There would be even less value in declaring the

presence of somatic dysfunction to practitioners from other professions, given the term is rarely used or understood outside the profession. Despite this, the author is aware of private practitioners and practitioners in teaching clinics that use this term in a written diagnosis.

The author has attempted in previous articles to provide a plausible explanation for the clinical phenomena attributed to somatic dysfunction, taking into account both functional changes and tissue comorbidities,<sup>8,9</sup> and has provided an updated model in this article. Given the model's focus on physical palpable signs, the factors considered in this model are largely biomedical, but the author does not wish to imply that practitioners should only consider biomedical factors in patient management. Management of patients should include consideration of tissue, neurological and biopsychosocial factors and this will be discussed in a future article.

#### Diagnostic reliability and validity

When considering the clinical meaningfulness of the term somatic dysfunction, diagnostic reliability and validity must be considered. For a clinical test to be useful, it should be reliable, where repeated measures by the same or different examiners yield the same result, and valid, where the test is measuring what it is intended to measure.<sup>83</sup> The diagnostic reliability of many of the indicators of somatic dysfunction is poor.<sup>84-86</sup> Palpation of tenderness has acceptable inter-examiner reliability, but reliability for palpation of segmental motion restriction or tissue texture changes is generally poor.<sup>84-86</sup> The reliability for assessment of asymmetrical bony landmarks is fair to poor,<sup>87</sup> unless substantial asymmetry exists.<sup>88</sup>

Evidence suggests that consensus training can substantially improve the reliability of these findings between practitioners,<sup>89,90</sup> although the validity of these consensus findings still remains to be explored. Other studies have found improved reliability when using a combination of diagnostic tests to detect symptomatic joints, provided pain provocation is

one of the test procedures.<sup>91-94</sup> However, these tests may simply be locating a symptomatic joint or region of hyperalgesia, which is not necessarily analogous to somatic dysfunction.

Further, the relevance of somatic dysfunction to health status or disease is unestablished. The validity of postural and structural asymmetry as indicators of dysfunction is dubious, given the lack of association with such findings and back pain.<sup>95</sup> A few researchers have attempted to link palpatory findings of somatic dysfunction to patient conditions,<sup>96,97</sup> but the poor reliability for detecting most of the clinical cues undermines the credibility of any reported associations. The lack of reliability for detection and lack of validity for association with pain or disease of these clinical signs undermines the traditional osteopathic claim that somatic dysfunction is important in health and disease.

#### Confounders for palpatory diagnosis

The osteopathic concept of somatic dysfunction is based on biomedical and biomechanical models, where physical clinical findings signal a functional abnormality and subsequent manipulative treatment normalises the function. In addition to poor diagnostic reliability, pain science further confounds the belief that palpation identifies a tissue basis for dysfunction. Palpation of tissue tenderness and texture changes are traditionally thought to implicate the underlying tissues, but tenderness of normal tissue may be evoked due to allodynia and CNS sensitisation and texture change may be produced in normal tissue from neurogenic inflammation in some individuals. Osteopaths must therefore be aware of the signs of central sensitisation, such as widespread pain and hyperalgesia, chronicity of symptoms, and intolerance to a variety of stimuli, to better interpret the relevance of their clinical findings.<sup>52</sup> This proposed conceptual model (Figure), along with a sound knowledge of pain science and signs of central sensitisation, may aid clinical reasoning and interpretation of physical findings.

#### The language of dysfunction

The medical language used with patients can have a powerful influence on a patient's appreciation of their condition. Communication can be reassuring and empowering or can be disempowering and reinforce fear avoidance behaviour and catastrophizing in patients. In recent decades, biopsychosocial factors in patients—such as their understanding (or misunderstanding) of their condition and their resultant behaviours to pain—have been suggested to have a strong influence on the course and prognosis of pain and disability.<sup>98,99</sup>

Historically, osteopathic manipulative treatment was developed within a biomechanical conceptual framework and has given rise to a disparate range of labels for alleged dysfunctions. The use of jargon terminology may be disempowering for many patients because essentially benign dysfunctions (typically minor movement impairments) may be interpreted as being serious impairments with long-term consequences and requiring ongoing passive manual treatment for correction.

The language associated with the 1950s Fryette biomechanical model,<sup>64</sup> a model commonly taught in the United States and Europe, typically uses complex 'positional' labels to describe segmental dysfunction. This model is still used in many current osteopathic texts,<sup>1, 5, 27, 100</sup> despite having been largely discredited.<sup>101-105</sup> Even though these positional terms are qualified as describing motion restriction or motion preference rather than joint positions,<sup>1</sup> the positional labels of dysfunction that include 'flexed and rotated' vertebra, 'anteriorly rotated' innominate bones, or 'superiorly subluxed' first ribs inevitably imply the erroneous concept of a 'bone out of place'. Using such language may confirm the impression of a serious structural disorder in the mind of a fearful and suffering patient, leading to catastrophizing, fear avoidance behaviour and unnecessary dependency on treatment.

In this author's view, positional terminology is anachronistic and potentially harmful. Motion restriction terminology is a preferable means of defining the motion characteristics of a segment because it does not reinforce the message of a fixed displacement in the mind of

the patient or practitioner. Even the use of the term ‘somatic dysfunction’ may convey a similar message to the patient unless it is deconstructed and demystified. This term arguably has little meaning when describing the characteristics of dysfunction to other osteopaths, let alone to patients, so the use of the term is best restricted to theoretical consideration of the nature of dysfunction and causes of palpatory signs.

At present, we know little about how often the term ‘somatic dysfunction’ is used, how much significance osteopaths place on it, and what messages osteopaths convey to their patients about their physical findings and diagnosis. It is likely that the use of this term in the profession varies greatly throughout the world. Therefore, the international osteopathic profession needs to examine, discuss, and research this topic in a collaborative way to deliver a cohesive, evidence-based message about this topic.

### CONCLUSION

A conceptual model has been presented that describes plausible causes of palpatory diagnostic cues commonly attributed to intervertebral somatic dysfunction. This model will assist the clinical reasoning of the practitioner when interpreting palpatory findings. Somatic dysfunction has not been presented as a single clinical entity, but as numerous neurological and comorbid tissue factors involved in a cycle of minor injury, degenerative change, and resultant nociceptive and neurological consequences. Palpation alone cannot differentiate the underlying causes of the clinical signs of dysfunction, so these signs must be interpreted in the context of the case history, injury, chronicity, and evidence of sensitisation.

Somatic dysfunction is a concept that is considered central to osteopathic philosophy by many in the profession. However, given the term’s lack of specificity, the likelihood that many factors contribute to the clinical signs, the lack of reliability for detecting most of the clinical features, and the disempowerment that may accompany the use of jargon medical

labels, it has been argued that this term has no clinical utility for diagnostic purposes or for communicating a diagnosis to patients or other practitioners. Thus, while the concept may have usefulness as a model for interpreting palpatory diagnostic signs and aiding clinical reasoning for manipulative treatment, its use as a diagnostic label in the practice setting should be abandoned. There is an ongoing need to investigate osteopathic theoretical concepts and reflect on the available evidence, so the author recommends that the international profession examine, reflect, and discuss this issue of somatic dysfunction in a considered and collaborative way.

#### REFERENCES

1. Greenman PE. Principles of Manual Medicine. 3rd ed. Philadelphia: Lippincott William & Wilkins; 2003.
2. Dove C. A History of the Osteopathic Vertebral Lesion. *British Osteopathic Journal* 1967;3.
3. Educational Council on Osteopathic Principles. Glossary of Osteopathic Terminology: American Association of Colleges of Osteopathic Medicine; 2011:<http://www.aacom.org/resources/bookstore/Documents/GOT2011ed.pdf>.
4. Patterson MM, Wurster RD. Somatic dysfunction, spinal facilitation, and viscerosomatic integration. In: Chila AG, editor. *Foundations of Osteopathic Medicine*. 3rd ed. Philadelphia, PA: Lippincott William & Wilkins; 2011, p. 118-133.
5. DiGiovanna EL, Schiowitz S, Dowling DJ. An Osteopathic Approach to Diagnosis & Treatment. 3rd ed. Philadelphia: Lippincott William & Wilkins; 2005.

6. Fryer G, Morris T, Gibbons P. The relationship between palpation of thoracic paraspinal tissues and pressure sensitivity measured by a digital algometer. *J Osteopath Med* 2004;**7**:64-69.
7. Korr IM. Clinical significance of the facilitated state. *Journal of American Osteopathic Association* 1954;**54**:277-282.
8. Fryer G. Somatic dysfunction: updating the concept. *Australian Journal of Osteopathy* 1999;**10**:14-19.
9. Fryer G. Intervertebral dysfunction: a discussion of the manipulable spinal lesion. *J Osteopath Med* 2003;**6**:64-73.
10. Gibbons P, Tehan P. The intervertebral lesion: a professional challenge. *British Osteopathic Journal* 2000;**22**:11 - 16.
11. Fryer G, Fossum C. Therapeutic mechanisms underlying muscle energy approaches. In: Fernández-de-las-Peñas C, Arendt-Nielsen L, Gerwin RD, editors. *Tension-Type and Cervicogenic Headache: Pathophysiology, Diagnosis, and Management*. Sudbury, MA: Jones and Bartlett Publishers; 2010, p. 221-229.
12. Gibbons P, Tehan P. Manipulation of the Spine, Thorax and Pelvis. An Osteopathic Perspective. 3rd ed. London: Churchill Livingstone; 2008.
13. Ehrenfeuchter WC, Kappler RE. Palpatory examination. *Foundations of Osteopathic Medicine*. 3rd ed. Philadelphia, PA: Lippincott Williams & Wilkins; 2011, p. 401-409.
14. Kimberly PE. The Kimberly Manual. Outline of Osteopathic Manipulative Procedures. 2006 ed. Marceline: Walsworth Publishing; 2006.
15. Stoddard A. Manual of Osteopathic Practice. London: Hutchinson & Co; 1969.
16. Bogduk N. Clinical Anatomy of the Lumbar Spine and Sacrum. 4th ed. New York: Churchill Livingstone; 2005.

17. Beresford ZM, Kendall RW, Willick SE. Lumbar facet syndromes. *Curr Sports Med Rep* 2010;**9**:50-56.
18. Nazarian LN, Zegel HG, Gilbert KR, Edell SL, Bakst BL, Goldberg BB. Paraspinal ultrasonography: lack of accuracy in evaluating patients with cervical or lumbar back pain. *J Ultrasound Med* 1998;**17**:117-122.
19. Fryer G, Adams JH. Magnetic resonance imaging of subjects with acute unilateral neck pain and restricted motion: a prospective case series. *The Spine Journal* 2011;**11**:171-176.
20. Webb AL, Collins P, Rassoulilian H, Mitchell BS. Synovial folds - a pain in the neck? *Man Ther* 2011;**16**:118-124.
21. Gatterman MI. *Foundations of Chiropractic: Subluxation*. 2nd ed. St Louis: Elsevier Mosby; 2005.
22. Cramer GD, Henderson CN, Little JW, Daley C, Grieve TJ. Zygapophyseal joint adhesions after induced hypomobility. *J Manipulative Physiol Ther* 2010;**33**:508-518.
23. Steilen D, Hauser R, Woldin B, Sawyer S. Chronic Neck Pain: Making the Connection Between Capsular Ligament Laxity and Cervical Instability. *The Open Orthopaedics Journal* 2014;**8**:326-345.
24. Nadeau M, McLachlin SD, Bailey SI, Gurr KR, Dunning CE, Bailey CS. A Biomechanical Assessment of Soft-Tissue Damage in the Cervical Spine Following a Unilateral Facet Injury. *The Journal of Bone & Joint Surgery* 2012;**94**:e156.
25. Frank CB, Hart DA, Shrive NG. Molecular biology and biomechanics of normal and healing ligaments--a review. *Osteoarthritis Cartilage* 1999;**7**:130-140.
26. Jung H-J, Fisher MB, Woo SLY. Role of biomechanics in the understanding of normal, injured, and healing ligaments and tendons. *Sports Medicine, Arthroscopy, Rehabilitation, Therapy, and Technology : SMARTT* 2009;**1**:9-9.

27. Ehrenfeuchter WC. Segmental motion testing. In: Chila AG, editor. *Foundations of Osteopathic Medicine*. 3rd ed. Philadelphia, PA: Lippincott William & Wilkins; 2011, p. 431-436.
28. Bogduk N, Aprill C, Derby R. Lumbar discogenic pain: state-of-the-art review. *Pain Med* 2013;**14**:813-836.
29. Cyriax J. *Textbook of Orthopaedic Medicine*. Vol 1. 7th ed. London: Balliere Tindall; 1978.
30. McKenzie RA. *The Lumbar Spine. Mechanical Diagnosis and Therapy*. Wellington: Spinal Publications; 1981.
31. Brinjikji W, Luetmer PH, Comstock B, et al. Systematic Literature Review of Imaging Features of Spinal Degeneration in Asymptomatic Populations. *AJNR*. *American journal of neuroradiology* 2015;**36**:811-816.
32. Nakashima H, Yukawa Y, Suda K, Yamagata M, Ueta T, Kato F. Abnormal findings on magnetic resonance images of the cervical spines in 1211 asymptomatic subjects. *Spine (Phila Pa 1976)* 2015;**40**:392-398.
33. Ellingson AM, Shaw MN, Giambini H, An KN. Comparative role of disc degeneration and ligament failure on functional mechanics of the lumbar spine. *Comput Methods Biomech Biomed Engin* 2015:1-10.
34. Colloca CJ, Keller TS, Moore RJ, Gunzburg R, Harrison DE. Intervertebral disc degeneration reduces vertebral motion responses. *Spine (Phila Pa 1976)* 2007;**32**:E544-550.
35. Indahl A, Kaigle A, Reikeras O, Holm S. Electromyographic response of the porcine multifidus musculature after nerve stimulation. *Spine (Phila Pa 1976)* 1995;**20**:2652-2658.

36. Fryer G, Morris T, Gibbons P. Paraspinal muscles and intervertebral dysfunction. Part 1. *J Manipulative Physiol Ther* 2004;**27**:267-274.
37. Fryer G, Morris T, Gibbons P. Paraspinal muscles and intervertebral dysfunction. Part 2. *J Manipulative Physiol Ther* 2004;**27**:348-357.
38. Fryer G, Bird M, Robbins B, Johnson J. Resting electromyographic activity of deep thoracic transversospinalis muscles identified as abnormal with palpation. *J Am Osteopath Assoc* 2010;**110**:61-68.
39. Korr IM. The neural basis of the osteopathic lesion. *J Am Osteopath Assoc* 1947;**47**:191-198.
40. Korr IM. Proprioceptors and somatic dysfunction. *J Am Osteopath Assoc* 1975;**75**:638-650.
41. Denslow JS, Clough GH. Reflex activity in the spinal extensors. *J Neurophysiol* 1941;**4**:430-437.
42. Denslow JS, Korr IM, Krems AD. Quantitative studies of chronic facilitation in human motoneuron pools. *Am J Physiol* 1947;**150**:229-238.
43. Korr IM, Wright HM, Thomas PE. Effects of experimental myofascial insults on cutaneous patterns of sympathetic activity in man. *Journal of Neural Transmission* 1962;**23**:330-355.
44. Lederman E. Facilitated segments: a critical review. *Br Osteopath J* 2000;**22**:7-10.
45. Franke H. Research and osteopathy: An interview with Dr Gary Fryer. *J Bodyw Mov Ther* 2010;**14**:304-308.
46. Van Buskirk RL. Nociceptive reflexes and the somatic dysfunction: a model. *J Am Osteopath Assoc* 1990;**90**:792-794, 797-809.

47. Fryer G, Bird M, Robbins B, Johnson JC. Electromyographic responses of deep thoracic transversospinalis muscles to osteopathic manipulative interventions. *International Journal of Osteopathic Medicine* 2013;**16**:e3-e4.
48. Woolf CJ. What to call the amplification of nociceptive signals in the central nervous system that contribute to widespread pain? *Pain* 2014;**155**:1911-1912.
49. Woolf CJ. Central sensitization: implications for the diagnosis and treatment of pain. *Pain* 2011;**152**:S2-15.
50. Latremoliere A, Woolf CJ. Central Sensitization: A Generator of Pain Hypersensitivity by Central Neural Plasticity. *The Journal of Pain* 2009;**10**:895-926.
51. Quinn KP, Dong L, Golder FJ, Winkelstein BA. Neuronal hyperexcitability in the dorsal horn after painful facet joint injury. *Pain* 2010;**151**:414-421.
52. Nijs J, Van Houdenhove B, Oostendorp RAB. Recognition of central sensitization in patients with musculoskeletal pain: Application of pain neurophysiology in manual therapy practice. *Manual Therapy* 2010;**15**:135-141.
53. Steinhoff M, Stander S, Seeliger S, Ansel JC, Schmelz M, Luger T. Modern aspects of cutaneous neurogenic inflammation. *Arch Dermatol* 2003;**139**:1479-1488.
54. Willis WD, Jr. Dorsal root potentials and dorsal root reflexes: a double-edged sword. *Exp Brain Res* 1999;**124**:395-421.
55. Sluka KA, Rees H, Westlund KN, Willis WD. Fiber types contributing to dorsal root reflexes induced by joint inflammation in cats and monkeys. *Journal of Neurophysiology* 1995;**74**:981-989.
56. Rees H, Sluka KA, Lu Y, Westlund KN, Willis WD. Dorsal root reflexes in articular afferents occur bilaterally in a chronic model of arthritis in rats. *Journal of Neurophysiology* 1996;**76**:4190-4193.

57. Willard F, Jerome JA, Mitchell LE. Nociception and pain: the essence of pain lies mainly in the brain. In: Chila AG, editor. *Foundations of Osteopathic Medicine*. 3rd ed. Philadelphia, PA: Lippincott William & Wilkins; 2011, p. 228-252.
58. Bo Peng Y, Kenshalo DR, Gracely RH. Periaqueductal gray-evoked dorsal root reflex is frequency dependent. *Brain Research* 2003;**976**:217-226.
59. Wallwork TL, Stanton WR, Freke M, Hides JA. The effect of chronic low back pain on size and contraction of the lumbar multifidus muscle. *Man Ther* 2009;**14**:496-500.
60. Hides JA, Richardson CA, Jull GA. Magnetic resonance imaging and ultrasonography of the lumbar multifidus muscle. *Spine* 1995;**20**:54-58.
61. Hides J, Gilmore C, Stanton W, Bohlscheid E. Multifidus size and symmetry among chronic LBP and healthy asymptomatic subjects. *Manual Therapy* 2008;**13**:43-49.
62. Fortin M, Macedo LG. Multifidus and Paraspinal Muscle Group Cross-Sectional Areas of Patients With Low Back Pain and Control Patients: A Systematic Review With a Focus on Blinding. *Physical Therapy* 2013;**93**:873-888.
63. Fryer G, Morris T, Gibbons P. The relationship between palpation of thoracic tissues and deep paraspinal muscle thickness. *Int J Osteopath Med* 2005;**8**:22-28.
64. Fryette HH. *Principles of Osteopathic Technic*. Newark, OH: American Academy of Osteopathy; 1954.
65. Schabrun SM, Elgueta-Cancino EL, Hodges PW. Smudging of the Motor Cortex is related to the Severity of Low Back Pain. *Spine (Phila Pa 1976)* 2015;**(in press)**.
66. Tsao H, Danneels LA, Hodges PW. ISSLS prize winner: Smudging the motor brain in young adults with recurrent low back pain. *Spine (Phila Pa 1976)* 2011;**36**:1721-1727.
67. Schabrun SM, Hodges PW, Vicenzino B, Jones E, Chipchase LS. Novel adaptations in motor cortical maps: the relation to persistent elbow pain. *Med Sci Sports Exerc* 2015;**47**:681-690.

68. Lederman E. The Science and Practice of Manual Therapy. 2nd ed. Edinburgh: Elsevier Churchill Livingstone; 2005.
69. Saccò M, Meschi M, Regolisti G, et al. The Relationship Between Blood Pressure and Pain. The Journal of Clinical Hypertension 2013;**15**:600-605.
70. Sjolander P, Michaelson P, Jaric S, Djupsjobacka M. Sensorimotor disturbances in chronic neck pain: range of motion, peak velocity, smoothness of movement, and repositioning acuity. Man Ther 2008;**13**:122-131.
71. Grip H, Sundelin G, Gerdle B, Karlsson JS. Variations in the axis of motion during head repositioning: a comparison of subjects with whiplash-associated disorders or non-specific neck pain and healthy controls. Clin Biomech (Bristol, Avon) 2007;**22**:865-873.
72. Lee HY, Wang JD, Yao G, Wang SF. Association between cervicocephalic kinesthetic sensibility and frequency of subclinical neck pain. Man Ther 2008;**13**:419-425.
73. de Vries J, Ischebeck BK, Voogt LP, et al. Joint position sense error in people with neck pain: A systematic review. Man Ther 2015;**(in press)**.
74. Ruhe A, Fejer R, Walker B. Altered postural sway in patients suffering from non-specific neck pain and whiplash associated disorder - A systematic review of the literature. Chiropr Man Therap 2011;**19**:13.
75. Mazaheri M, Coenen P, Parnianpour M, Kiers H, van Dieën JH. Low back pain and postural sway during quiet standing with and without sensory manipulation: A systematic review. Gait & Posture 2013;**37**:12-22.
76. Ruhe A, Fejer R, Walker B. Center of pressure excursion as a measure of balance performance in patients with non-specific low back pain compared to healthy

- controls: a systematic review of the literature. *European Spine Journal* 2011;**20**:358-368.
- 77.** Zedka M, Prochazka A, Knight B, Gillard D, Gauthier M. Voluntary and reflex control of human back muscles during induced pain. *Journal of Physiology* 1999;**520**:591-604.
- 78.** Videman T, Battie MC, Ripatti S, Gill K, Manninen H, Kaprio J. Determinants of the progression in lumbar degeneration: a 5-year follow-up study of adult male monozygotic twins. *Spine (Phila Pa 1976)* 2006;**31**:671-678.
- 79.** Videman T, Battie MC, Parent E, Gibbons LE, Vainio P, Kaprio J. Progression and determinants of quantitative magnetic resonance imaging measures of lumbar disc degeneration: a five-year follow-up of adult male monozygotic twins. *Spine (Phila Pa 1976)* 2008;**33**:1484-1490.
- 80.** Bogduk N. Degenerative Joint Disease of the Spine. *Radiologic Clinics of North America* 2012;**50**:613-628.
- 81.** Young M. Humpty Dumpty chiropractic. *Clinical Chiropractic* 2010;**13**:197-198.
- 82.** World Health Organisation. International Classification of Diseases (ICD). Available at: <http://apps.who.int/classifications/icd10/browse/2016/en#/M99>. Accessed 2nd October, 2015.
- 83.** Lucas N, Bogduk N. Diagnostic reliability in osteopathic medicine. *International Journal of Osteopathic Medicine* 2011;**14**:43-47.
- 84.** Seffinger MA, Najm WI, Mishra SI, et al. Reliability of spinal palpation for diagnosis of back and neck pain: a systematic review of the literature. *Spine (Phila Pa 1976)* 2004;**29**:E413-E425.
- 85.** Triano JJ, Budgell B, Bagnulo A, et al. Review of methods used by chiropractors to determine the site for applying manipulation. *Chiropr Man Therap* 2013;**21**:36.

86. Stochkendahl MJ, Christensen HW, Hartvigsen J, et al. Manual Examination of the Spine: A Systematic Critical Literature Review of Reproducibility. *J Manipulative Physiol Ther* 2006;**29**:475-485.
87. Haneline MT, Young M. A Review of Intraexaminer and Interexaminer Reliability of Static Spinal Palpation: A Literature Synthesis. *Journal of Manipulative and Physiological Therapeutics* 2009;**32**:379-386.
88. Fryer G. Factors affecting the intra-examiner and inter-examiner reliability of palpation for supine medial malleoli asymmetry. *Int J Osteopath Med* 2006;**9**:58-65.
89. Degenhardt BF, Johnson JC, Snider KT, Snider EJ. Maintenance and improvement of interobserver reliability of osteopathic palpatory tests over a 4-month period. *J Am Osteopath Assoc* 2010;**110**:579-586.
90. Degenhardt BF, Snider KT, Snider EJ, Johnson JC. Interobserver Reliability of Osteopathic Palpatory Diagnostic Tests of the Lumbar Spine: Improvements From Consensus Training. *Journal of American Osteopathic Association* 2005;**105**:465-473.
91. Jull G, Zito G, Trott P, Potter H, Shirley D. Inter-examiner reliability to detect painful upper cervical joint dysfunction. *Aust J Physiother* 1997;**43**:125-129.
92. Jull GA, Bogduk N, Marsland A. The accuracy of manual diagnosis for cervical zygapophysial joint pain syndromes. *Medical Journal of Australia* 1988;**148**:233-236.
93. Jull GA, Treleaven J, Versace G. Manual examination: is pain provocation a major cue for spinal dysfunction? *Australian Journal of Physiotherapy* 1994;**40**:159-165.
94. Phillips DR, Twomey LT. A comparison of manual diagnosis with a diagnosis established by a uni-level lumbar spinal block procedure. *Man Ther* 1996;**2**:82-87.
95. Lederman E. The fall of the postural-structural-biomechanical model in manual and physical therapies: Exemplified by lower back pain. *Journal of Bodywork and Movement Therapies* 2011;**15**:131-138.

96. Licciardone JC, Fulda KG, Stoll ST, Gamber RG, Cage AC. A case-control study of osteopathic palpatory findings in type 2 diabetes mellitus. *Osteopathic Medicine and Primary Care* 2007;**1**:1-12.
97. Licciardone JC, Kearns CM, Hodge LM, Minotti DE. Osteopathic manual treatment in patients with diabetes mellitus and comorbid chronic low back pain: subgroup results from the OSTEOPATHIC Trial. *J Am Osteopath Assoc* 2013;**113**:468-478.
98. Kamper SJ, Apeldoorn AT, Chiarotto A, et al. Multidisciplinary biopsychosocial rehabilitation for chronic low back pain. *Cochrane Database Syst Rev* 2014;**9**:CD000963.
99. Pincus T, Kent P, Bronfort G, Loisel P, Pransky G, Hartvigsen J. Twenty-five years with the biopsychosocial model of low back pain-is it time to celebrate? A report from the twelfth international forum for primary care research on low back pain. *Spine (Phila Pa 1976)* 2013;**38**:2118-2123.
100. Mitchell Jr FL, Mitchell PKG. *The Muscle Energy Manual. Vol 1.* East Lansing, Michigan: MET Press; 1995.
101. Fryer G. Muscle energy technique: An evidence-informed approach. *Int J Osteopath Med* 2011;**14**:3-9.
102. Cook C, Sizer P, Jr., Brismee JM, Showalter C, Huijbregts P. Does evidence support the existence of lumbar spine coupled motion? A critical review of the literature. *J Orthop Sports Phys Ther* 2007;**37**:412.
103. Gibbons P, Tehan P. Muscle energy concepts and coupled motion of the spine. *Man Ther* 1998;**3**:95-101.
104. Legaspi O, Edmond SL. Does the Evidence Support the Existence of Lumbar Spine Coupled Motion? A Critical Review of the Literature. *J Orthop Sports Phys Ther* 2007;**37**:169-178.

- 105.** Malmstrom E, Karlberg M, Fransson PA, Melander A, Magnusson M. Primary and Coupled Cervical Movements. The Effect of Age, Gender, and Body Mass Index. A 3-Dimensional Movement Analysis of a Population Without Symptoms of Neck Disorders. Spine 2006;**31**:E44-E50.

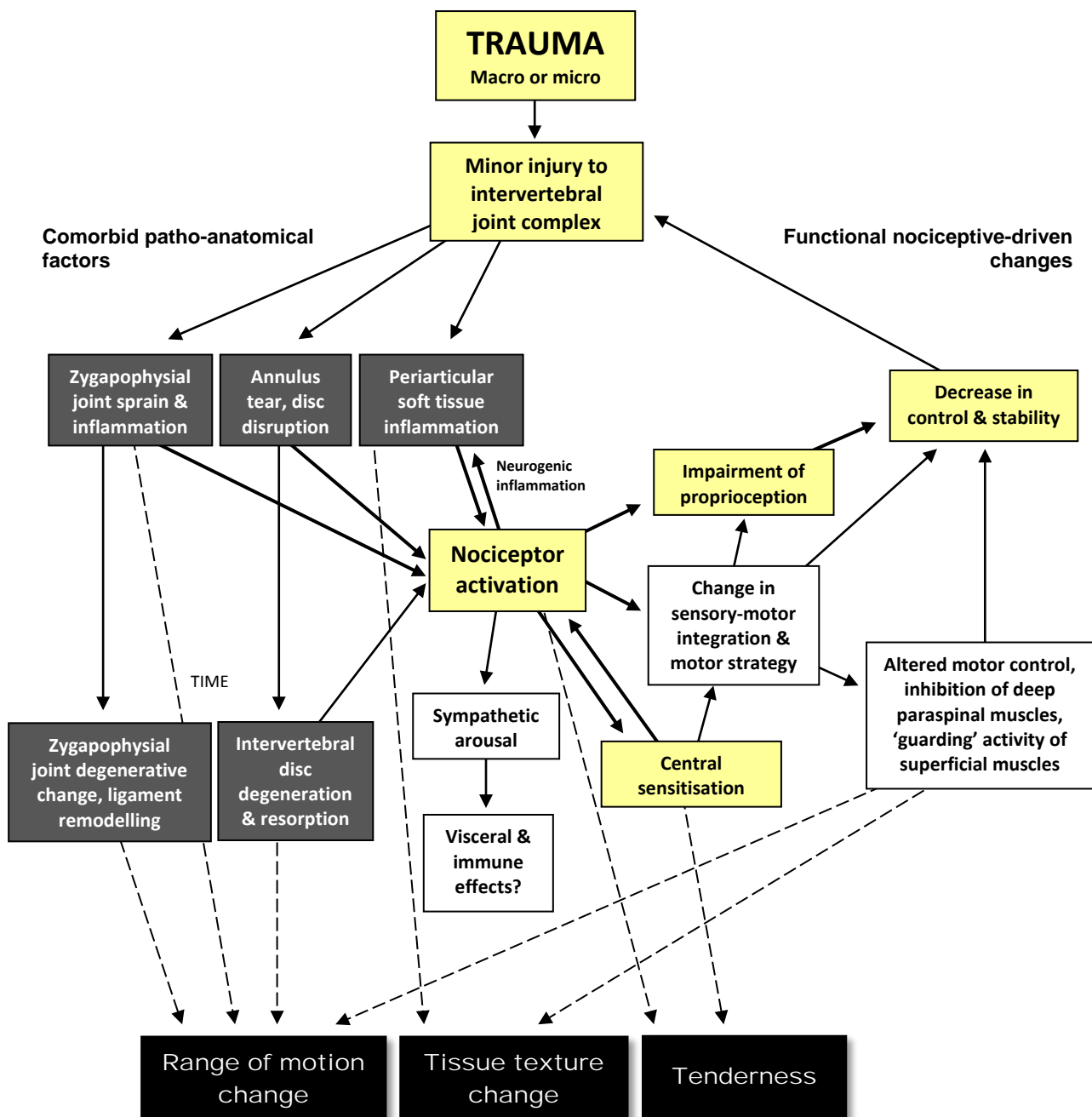


Figure: A model for the clinical signs attributed to intervertebral somatic dysfunction (modified from Fryer 2003). The clinical signs of tenderness, range of motion change, and tissue texture change are accounted for in this model. The clinical sign of asymmetry will be evident if the above tissue factors affect one side of the intervertebral segment more than the other side.