

interest for assessing gastric contents? A preliminary report. *Eur J Anaesth* 2009; 26: 1015–9

5. Spencer AO, Walker AM, Yeung AK, et al. Ultrasound assessment of gastric volume in the fasted pediatric patient undergoing upper gastrointestinal endoscopy: development of a predictive model using endoscopically suctioned volumes. *Paediatr Anaesth* 2015; 25: 301–8
6. Tomomasa T, Tabata M, Nako Y, et al. Ultrasonographic assessment of intragastric volume in neonates: factors affecting the relationship between intragastric volume and antral cross-sectional area. *Pediatr Radiol* 1996; 26: 815–20
7. Schmitz A, Thomas S, Melanie F, et al. Ultrasonographic gastric antral area and gastric contents volume in children. *Paediatr Anaesth* 2012; 22: 144–9

doi:10.1093/bja/aev122

Structured approach to ultrasound-guided identification of the cricothyroid membrane: a randomized comparison with the palpation method in the morbidly obese

M. S. Kristensen*, W. H. Teoh, S. S. Rudolph, M. F. Tvede, R. Hesselheldt, J. Børglum, T. Lohse, and L. N. Hansen

Copenhagen, Denmark

*E-mail: michael.seltz.kristensen@regionh.dk

Editor—Correct identification of the cricothyroid membrane is crucial in preparation for emergency airway management. However, the conventional method, inspection and palpation, has a low success rate,¹ especially in women (24–35%).² We have previously described a structured stepwise method for ultrasonographic identification of the cricothyroid membrane,^{3 4} in which it is not necessary to see or palpate any landmarks on the neck for successful identification. The method involves ultrasonographic identification of the trachea in the transverse plane, rotating the transducer to the longitudinal plane, and identifying the image of the anterior parts of the tracheal rings and the cricothyroid cartilage. Using its ability to cast a shadow on the ultrasound image, an i.v. needle is slid between the transducer and the skin, without penetrating the skin, until it is immediately cranial to the cricoid cartilage, thus indicating the cricothyroid membrane (Fig. 1).

We tested the effectiveness of the stepwise approach in the hand of airway-ultrasound naïve anaesthetists. After Ethics Committee approval, written consent, and trial registration, 35 anaesthetists, with a mean of 6 yr experience in clinical

anaesthesia, completed a structured training programme consisting of an e-learning module, followed by a 20 min lecture, and 20 min hands-on training on live models. Subsequently, the anaesthetists' ability to identify the cricothyroid membrane both with the palpation method and with ultrasonography was tested in a crossover randomized-sequence test on a morbidly obese female, height 166 cm, weight 125 kg, and BMI 45.3 kg m⁻².

Both attempts were timed and videotaped. The timing started when the finger or the ultrasound probe touched the skin of the neck. With both methods, the anaesthetist was instructed to place an i.v. needle (as a marker) transversely on the skin where he or she found the cricothyroid membrane to be. When the palpation attempt was completed, the examiner placed the ultrasound probe longitudinally on the trachea so that the exact location of the needle in relation to the cricothyroid membrane could be verified. The two attempts were judged independently both by the examiner on site and, subsequently, by another expert using only the video recording. The latter expert was blinded to the examiner's judgement.

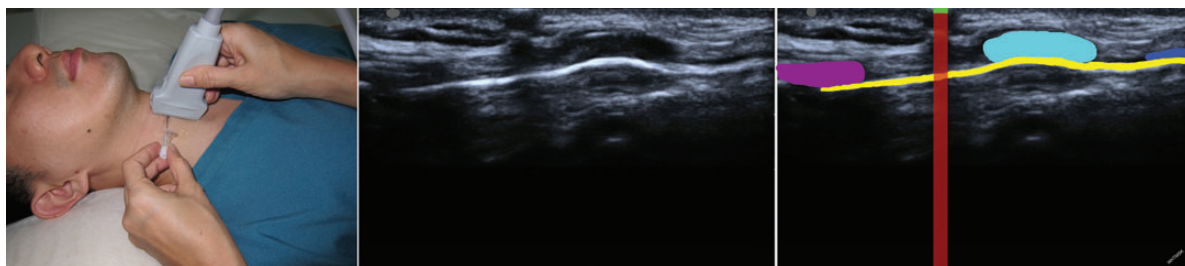


Fig 1 Yellow shows the tissue–air border, the mucosal lining in the trachea. The distal part of the thyroid cartilage (purple) is seen. The cricothyroid membrane can be identified by sliding a needle (used only as a marker) underneath the ultrasonography transducer from the cranial end until it casts a shadow (red line) immediately cranial to the cricoid cartilage (turquoise). The green spot represents the reflection from the needle. Care is taken not to touch the patient with the sharp tip of the needle.

When using the conventional digital palpation method, 13 of 35 anaesthetists (37%; 95% confidence interval, 21–55%) were able to locate the cricothyroid membrane successfully within 2 min, whereas the success rate was 29 of 35 (83%; 95% confidence interval, 66–93%) when the structured stepwise ultrasonography method was applied ($P=0.0008$, McNemar's test). This was achieved in a median [range] of 18 [5–45] s for the 13 instances of successful identification by palpation and in 48 [26–112] s for the 29 instances of successful ultrasound-guided identification of the cricothyroid membrane.

The results show that after a short dedicated teaching programme and using a structured approach, anaesthetists can obtain a significantly higher rate of successful identification of the cricothyroid membrane than when they use their standard method, palpation. However, it took 48 [26–112] s to do so, which indicates that this method should be applied before managing a difficult airway, and not once hypoxia is already present.

In all airway guidelines, the recommended ultimate escape is oxygenation via the cricothyroid membrane. We should thus attempt to identify this structure before induction of anaesthesia.⁵ Often this can be done by inspection or palpation alone, but for use in the remaining patients, our results demonstrate that ultrasonographic identification using the structured stepwise

approach is applicable and that the technique can be learned in a short time by ultrasound-naïve anaesthetists.

Declaration of interest

None declared.

References

1. Elliott DS, Baker PA, Scott MR, Birch CW, Thompson JM. Accuracy of surface landmark identification for cannula cricothyroidotomy. *Anaesthesia* 2010; **65**: 889–94
2. Lamb A, Zhang J, Hung O, et al. Accuracy of identifying the cricothyroid membrane by anesthesia trainees and staff in a Canadian institution. *Can J Anaesth* 2015; **62**: 495–503
3. Kristensen MS. Ultrasonography in the management of the airway. *Acta Anaesthesiol Scand* 2011; **55**: 1155–73
4. Kristensen MS, Teoh WH, Graumann O, Laursen CB. Ultrasonography for clinical decision-making and intervention in airway management: from the mouth to the lungs and pleurae. *Insights Imaging* 2014; **5**: 253–79
5. Kristensen MS, Teoh WH, Baker PA. Percutaneous emergency airway access; prevention, preparation, technique and training. *Br J Anaesth* 2015; **114**: 357–61

doi:10.1093/bja/aev123

French regional trauma network: the Rhone-Alpes example

P. Bouzat*, J. S. David, and K. Tazarourte

Grenoble, France

*E-mail: pbouzat@chu-grenoble.fr

Editor—We read with great interest the special issue of the *British Journal of Anaesthesia* dedicated to severe trauma care in the UK.¹ The trauma system implemented in the British territory is remarkable and this issue highlighted the need for worldwide implementation of national trauma networks.

In France, regional networks for trauma care have been developed in the Rhone-Alpes region for a decade. RESUVAL (trauma network of the Rhone Valley) and TRENAU (trauma system of the Northern French Alps Emergency Network) federate 40 hospitals within a regional area (Drome, Rhone, Ain, Isere, Savoie and Haute Savoie, France) and combine the American trauma system's organization and the French expertise in pre-hospital medical care. In France, the Service d'Aide Medicale Urgente (SAMU) and the Service Medical d'Urgence et de Reanimation (SMUR) were created to face the poliomyelitis epidemic in the 1950s and to provide pre-hospital medical care for trauma all over the country. In practice, trauma care accounts for only 15% of all pre-hospital emergencies, and a majority of the activity is represented by myocardial infarction, stroke and cardiac arrest. Triage algorithms based on medical assessment and management at the scene have been proposed for patients with severe blunt trauma.

The triage procedure integrates the initial assessment of the trauma severity by pre-hospital physicians, the need for medical facilities and the proximity of trauma centres. After medical assessment, trauma patients are categorized into three levels of

severity according to criteria of injury severity and the response of pre-hospital resuscitation. This triage procedure aims to admit trauma patients to the most suitable trauma centre according to their available facilities to avoid secondary potentially harmful transfer.

Marked differences should be noted between the French and the British trauma networks. Evaluation by the pre-hospital medical team is one of the hallmarks of the French trauma system. The effects of pre-hospital medical management were recently assessed in the French Intensive Care Recorded in Severe Trauma (FIRST) study. In a cohort of 2700 patients with severe blunt trauma, pre-hospital management with SMUR was associated with a significantly reduced mortality on day 30 after the injury. Interestingly, adjustments for the time delay from accident to hospital admission marginally affected these results. Another advantage of pre-hospital medical evaluation could be the rapid assessment of trauma severity by ultrasonography to improve pre-hospital triage. Another specific feature is the anaesthesiologist-intensivist leadership in the trauma team at hospital admission.

The French regional network for trauma care developed in the Rhone-Alpes region is a specific adaptation of the American trauma system to the organization of pre-hospital medical care in France. Because the effect of the trauma system on mortality after severe trauma is well documented, trauma networks should be implemented in all French territory. The British organization, with its national networking, shows us the path.